




ORIGINAL ARTICLE

Uterus procurement from deceased donor for transplantation

Felipe Castro^{1,2,3,4} , Dani Ejzenberg², Rafael S. Pinheiro¹, Liliana Ducatti¹, Rubens M. Arantes¹, Lucas Nacif¹, Daniel Waisberg¹, Rodrigo B. Martino¹, Vinicius R. Santos¹, Jose Maria Soares Jr², Edmund Chada Baracat², Luiz Augusto Carneiro D'Albuquerque¹, Wellington Andraus¹, Hoover Canaval³, Gustavo Canaval³, Juan Manuel Rico⁴ & Anabel Vanin⁴

1 Department of Liver and Digestive Tract Organ Transplantation, Hospital das Clínicas, University of São Paulo Medical School, São Paulo, Brazil

2 Department of Gynecology and Obstetrics, Hospital das Clínicas, University of São Paulo Medical School, São Paulo, Brazil

3 Department of Gynecology and Obstetrics, Clinica Imbanaco, Cali, Colombia

4 Department of Liver Transplantation, Clinica Imbanaco, Cali, Colombia

Correspondence

Felipe Castro, Av. 4 oeste # 5 – 250, Cali 760045, Colombia
Tel.: 57 310 4652431;
e-mail: felipe.castrov81@gmail.com

SUMMARY

Women with absolute uterine factor infertility cannot get pregnant. The current experience in uterine transplantation is limited and the use of a deceased donor uterus in this area is incipient after some initial unsuccessful attempts. The birth of healthy babies through this modality in four different centers has given a new impetus to the use of this transplantation technique. We aimed to develop a technique for uterus procurement and preparation for transplantation from a brain dead donor. Fifteen uteri were retrieved from multi-organ donor patients, 10 of these were used in bench surgeries with the proposed technique. All procedures were performed after obtaining family's consent. This study allowed the clinical use of two of the 15 organs that were procured for transplantation. One of these organs resulted in the first live birth worldwide using a uterus transplanted from a deceased donor, a landmark in reproductive medicine. Another outcome was the optimization of the surgical technique involving less manipulation of the uterine vascular pedicles. The success of this novel technique suggests that the proposed model can be replicated and optimized further to facilitate the transplantation of uterus from deceased donors.

Transplant International 2021; 34: 2570–2577

Key words

absolute uterine factor infertility, deceased donor, multiple organs, procurement, transplantation, uterus

Received: 2 February 2021; Revision requested: 6 October 2021; Accepted: 17 October 2021;
Published online: 10 November 2021

Introduction

The introduction of *in vitro* fertilization (IVF) in 1978 was a remedy for many infertile couples; however, the only options available to patients with absolute uterine factor infertility (AUI) due to congenital or acquired causes and desiring children were adoption or the utilization of gestational surrogacy [1,2]. The congenital causes of uterine factor, involving the absence or

malformation of the uterus, affect approximately one in 500 women. Emergency hysterectomy is one of the acquired causes of AUI, with an incidence of 0.6–2.3 per 1000 women [3,4]. Uterine transplantation emerged as a new treatment option for these patients.

Uterine transplantation was first performed clinically in Saudi Arabia in 2000; however, the allograft had to be removed 99 days post-transplantation due to vascular thrombosis [5]. The second attempt was made in

2011 in Turkey, this time the uterus was from a deceased donor, the transplant was technically successful, but there are no data of birth until now [6]. In 2014, a Swedish group reported a series of nine uterine transplants from living donors that resulted in seven live births and two uterine losses due to infection and thrombosis [7–11]. The first live birth, following a living donor transplantation, in the United States was reported in 2017 [12], and the first live birth following a deceased donor was reported in Brazil in December 2017 [13]. The second successful transplantation from a deceased donor was reported by a team from Cleveland in 2019 [14]. So far, reports of transplants have been published in several countries, 18 cases involving deceased donors (resulting in five births) [14–20].

If the transplantation of organs procured from deceased donors is successful as living donor transplants, it could universalize the access to the procedure, eliminate the risks for the living donor, and reduce the total cost of the process. Therefore, it is essential to develop the procurement technique and bench surgery to reduce bleeding or thrombosis in the recipient, shorten ischemia time, and increase the rates of success without putting at risk the other organs intended for transplantation.

The objective of the present study was to standardize the method of retrieval and preparation of the deceased donor's uterus for transplantation and discuss the points for the improvement and further development of the technique.

Methods

The study involved the procurement of 10 uteri from brain dead multi-organ donors in the city of São Paulo, donated by the State Transplantation Service (Serviço Estadual de Transplantes) between August 2016 and March 2017, and 5 uteri from donors in the city of Cali, Colombia, between June 2019 and February 2020. When organ removal was deemed satisfactory, based on adequate perfusion of the organ or absence of thrombosis or vascular lesion of the uterine pedicles, bench surgery was performed to prepare the vascular pedicles for transplantation at the Hospital das Clínicas of the University of São Paulo Medical School, Brazil, and at the Clínica Imbanaco in Cali, Colombia.

An experimental study involving autotransplantation in 10 sheep was conducted before starting the present project, at the laboratory of medical investigation 37 (LIM) of the Liver Transplantation course of the University of São Paulo Medical School [21].

All surgeries were performed in agreement with other abdominal transplant teams from the region in São Paulo, in Colombia the retrieval of abdominal organs were performed by the same team.

The retrieval procedure was based on the team's previous experience in the procurement of other solid organs such as the liver and pancreas and on the Swedish study with living donors [7]. Moreover, it was adapted to the local reality, involving multiple organ procurement from a deceased donor.

The inclusion and exclusion criteria for organ procurement are listed in Table 1. These criteria were applied solely to donors whose uteri were used for transplantation. They were not applied to donors whose organs were used with the sole purpose of technical training.

Surgical technique

Dissection of the uterus before its removal “warm phase”

Vigorous vaginal antiseptis with 10% iodopovidone solution (Figs 1 and 2).

Digital vaginal examination and speculum examination to rule out any lesions in the uterine cervix.

Disinfection of the operating field followed by abdominal–thoracic midline incision. Macroscopic assessment of the uterus features color, surface homogeneity, and presence of focal lesions.

Access to the operating field after complete dissection by the other teams (heart, liver, kidneys).

Isolation and section of the right round ligament (1).
Dissection and isolation of the gonadal vessels (2) and right ureter (3).

Dissection and isolation of the common iliac artery (4) and right distal external iliac artery.

Table 1. Selection criteria.

Inclusion criteria	Exclusion criteria
Age <45 years	History of uterine tumor
History of at least one pregnancy with a live birth	History of uterine malformation
Signed informed consent	Body mass index >35 kg/m ²
Hemodynamically compensated	More than two previous cesarean section
Negative for papilloma virus	
Negative for gonorrhea, chlamydia, and syphilis	
Negative for hepatitis B, C, HIV, and HTLV	

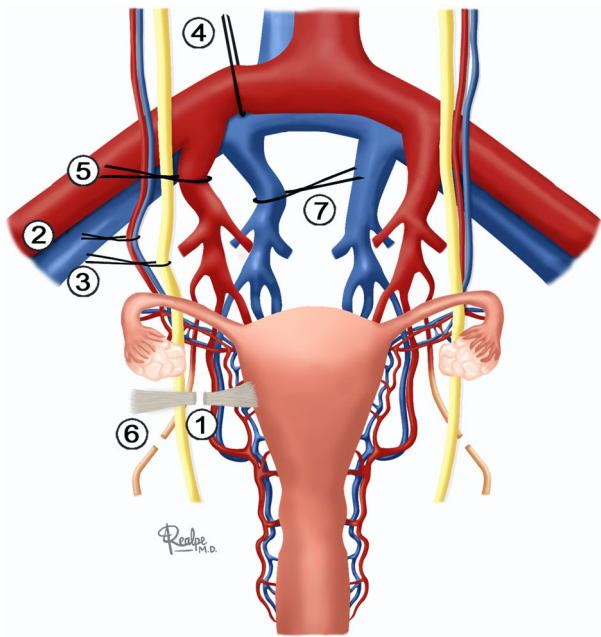


Figure 1 Warm phase of the surgery.

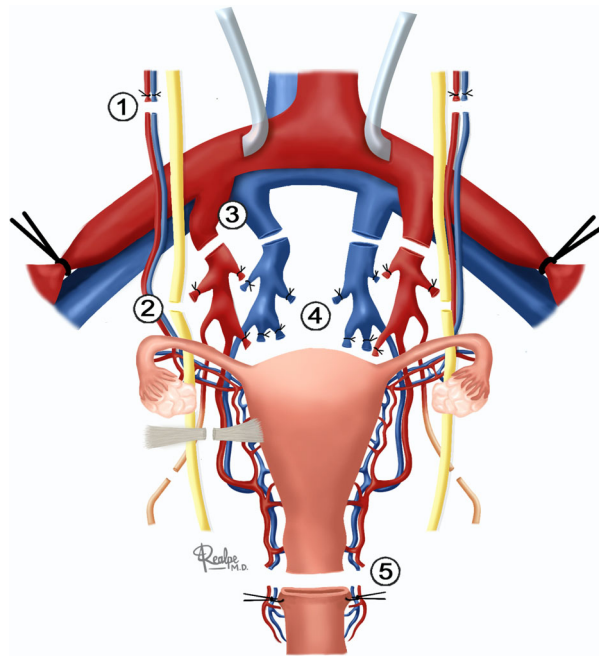


Figure 3 Cold phase of the surgery.

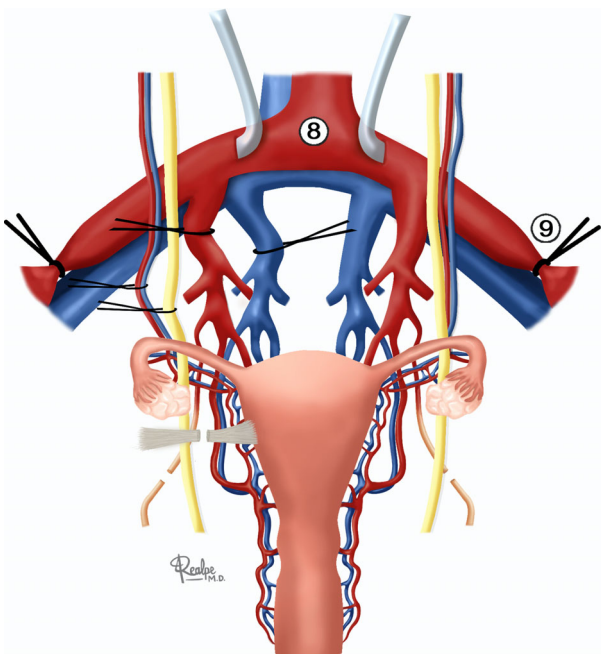


Figure 2 Cannulation and perfusion.

Dissection and isolation of the right internal iliac artery (5).
 Isolation and section of the right obliterated umbilical artery (6).
 Dissection and isolation of the right internal iliac vein (7).
 Thereafter, the same procedures were performed on the left side.

After bilateral dissection, the sacral branches of the posterior and anterior divisions of the internal iliac artery were ligated, leaving only the patent uterine arteries.

Systemic heparinization was then performed, with a clamp placed on the infrarenal aorta, followed by the cannulation of the common iliac artery bilaterally and separately with a urethral catheter gauge 18 (8) and subsequent ligation of the distal external iliac artery bilaterally (9).

Prior to cannulation for the perfusion of the other abdominal organs, 1000 ml of Custodiol+ 5000 IU of heparin were infused in each common iliac artery using a separate perfusion system for each artery and a 60-ml syringe on each side to increase the infusion pressure and the flow of the solution into the uterus.

Excision of the uterus “cold phase”

Sectioning of the gonadal vessels (1) longest as possible, thinking in a future anastomosis at the transplant to improve the outflow (Fig. 3).
 Sectioning of the ureters at their distal segments at least 2 cm after they cross over iliac common vessels (2), this was performed in agreement with the kidney transplant team; in cases performed in Colombia, all abdominal organs were retrieved by the same team.

Sectioning of the right internal iliac artery (3).

Sectioning of the right internal iliac vein (4).

Thereafter, the same procedures were performed on the left side.

Sectioning of the uterosacral ligament.

Dissection of the uterus from the posterior wall of the bladder.

Detachment of the rectum at its portion below the vagina.

Repair suturing in the vagina with vicryl-0, vaginal section at 3 cm from the cervix, and suturing of the donor's vaginal vault with vicryl-0 (5).

Excision of the organ.

In our final description, perfusion began immediately after clamping the infrarenal aorta, because it is at this point that uterine ischemia commences. Therefore, perfusion of the organ with preservation solution was started before clamping the thoracic or supraceliac aorta, which is performed for the excision of the liver, kidneys, pancreas, heart, and lungs.

Back table

Perfusion with 100 ml Custodiol through each uterine artery.

Bench surgery

Ligation of the branches of the uterine arteries and veins with 4-0 cotton thread.

Preparation of the internal iliac artery patch.

Testing of the gonadal and uterine veins.

Testing of the uterine arteries (test performed by infusing preservation solution into the arteries, with a positive result obtained if the solution is seen exiting the gonadal and uterine veins).

Approvals from ethics committees

The project of uterine transplantation with a deceased donor was approved by the following committees: National Committee on Research Ethics (CONEP) (03/06/2016 CAAE: 45068815.3.0000.0065), Brazilian National Transplantation System (SNT), Ethics Committee of the Hospital das Clínicas of the School of Medicine (registration number 13122), and Ethics Committee of the Clínica Imbanaco (Record no.5, March 2019, Cali, Colombia).

All organs were procured with the authorization of the central transplantation office (Central de Transplantes) of the city of São Paulo and with the consent

of the donors' families, both for research and clinical purposes.

Results

Fifteen uteri from brain dead multi-organ donors were procured, 10 in the city of São Paulo, Brazil, between August 2016 and March 2017, and 5 in the city of Cali, Colombia, between June 2019 and February 2020. Complementary bench dissections were performed for the preparation of the vascular pedicles in 10 of these organs, at the Instituto Central of the Hospital das Clínicas of the University of São Paulo Medical School, and at the Clínica Imbanaco of Cali. The patients' age ranged between 25 and 68 years (mean: 44.1 years).

The body mass index (BMI) varied between 20.7 and 36.6 kg/m² (mean: 27.5 kg/m²). Seven patients had hypertension (HT).

The first six retrievals were performed with the aim of developing and standardizing the surgical technique. From the seventh case onward, the organs were also eligible for clinical use in uterine transplantation and were perfused through the common iliac arteries and on the back table after organ excision. All retrievals were performed by the same surgeon. Dissection before cardiac arrest (warm phase) lasted between 24 and 56 min (mean: 41.6 min), perfusion with preservation solution lasted from 5 to 22 min (mean: 12.4 min), and the duration of the cold phase was between 15 and 55 min (mean: 26.6 min). Bench dissection required between 15 and 110 min (mean: 57.6 min) and the weight of the uterus after bench surgery varied between 115 and 255 g (mean: 175.4 g) (Table 2).

In three cases (D1, D2, and D5), it was not possible to precisely determine the time spent dissecting and removing the organ because of hemodynamic complications: one case of cardiac arrest, one case of loss of the aortic perfusion cannula, and one case of refractory hemodynamic instability that led to prioritizing the removal of the other organs (Table 2).

The uteri of two donors (donors 7 and 9) were used for transplantation. The total ischemic time of the organ of donor 7 was 7 h and 50 min and the recipient underwent a process of transfer of a single embryo 7 months after transplantation that resulted in the birth—at around 36 weeks of gestation, by cesarean section—of the first ever child born from a uterus transplanted from a deceased donor, without complications [13]. The total ischemic time of the organ of donor 9 was 8 h and 20 min and thrombosis of the uterine vessels occurred on postoperative day 3. The allograft was removed from the recipient who was discharged 3 days after the excision, without complications.

Table 2. Physical description of the donors, clinical history, surgical times, graft weight, and use in transplantation.

Age (years)	Weight (kg)	Height (cm)	BMI (kg/m ²)	Comorbidities	Warm phase (min)	Perfusion (min)	Cold phase (min)	Back table (min)	Weight of the graft (g)	Used for tx
D 1	55	162	20.9	Drug use	-	-	-	-	-	-
D 2	70	155	29.1	HT	-	-	-	-	-	-
D 3	84	165	30.8	HT	40	5	20	65	195	-
D 4	102	167	36.6	HT	37	20	20	-	-	-
D 5	72	159	28.5	-	-	-	-	39	160	-
D 6	65	168	23	HT + smoker	50	22	15	-	140	-
D 7	68	155	28.3	-	50	18	50	110	255	+
D 8	80	155	33.3	HT	50	-	20	-	115	-
D 9	65	165	23.8	Smoker	52	10	35	100	200	+
D 10	70	165	25.7	-	45	8	55	15	164	-
D 11	72	163	27.1	Smoker	56	13	21	-	-	-
D 12	53	160	20.7	Smoker	24	13	25	-	-	-
D 13	80	165	29.4	HT + smoker	28	6	26	25	198	-
D 14	70	163	26.4	HT	30	10	15	52	176	-
D 15	44	153	29.9	-	38	12	18	55	151	-

kg: kilograms; cm: centimeters; BMI: Body Mass Index; kg/m²: kilograms/square meter; min: minutes; HT: hypertension

Discussion

So far, only a few studies have attempted to determine the best technique for the removal of the uterus from a deceased donor for transplantation, and consolidated data on the maximum time of ischemia that allows the viability of the graft are also scarce [22,23].

An important aspect is the difficulty in dissecting the pelvic vessels, namely the uterine pedicles. During the surgeries performed to improve the technique, we started dissecting the arteries and the internal iliac veins and their branches during the warm ischemia phase, leaving only the patent uterine vessels, which were ligated and sectioned during the cold phase of the surgery (cold ischemia) (after clamping the aorta and removing vital organs). This explains the variability in the duration of each phase. Vascular pedicle dissection was performed at segments increasingly distal to the uterus to reduce the risk of vascular lesion and impairment of the graft for implantation (Fig. 4). We did not have more cases of vascular lesion after donor 8 because of the improvements in the technique made by the team and the acquired familiarity with the anatomical variability of the pelvic vessels. Vaginal sectioning was one of the most modified steps, until it was decided to repair the vagina before sectioning. This allowed an easier and quicker organ excision.

Cannulation of the common iliac arteries separately was not technically difficult, and we used independent systems of perfusing the preservation solution with one syringe for each side of the uterus, which allowed rapid and homogeneous perfusion. Perfusion was slow and heterogeneous in the first uterus perfused using a system without pressure. Because ischemia to the uterus commences when the arterial blood flow is interrupted to allow aortic cannulation for the perfusion of the other abdominal organs, the uterus was subjected to an initial period of warm ischemia, without preservation solution to flush the organ and without cooling. We started perfusing the organ before clamping the thoracic or supraceliac aorta, which permitted rapid cooling of the organ and reducing the warm ischemia time. With this perfusion modality, the preservation solution was almost completely used in the uterus and there was no effect on the removal and utilization of the other organs, also allowed us to use the preservation solution of our choice. Custodiol was used as a preservation solution, based on the predominantly muscular composition of the uterus and the heart (for which it is commonly used) and on its low viscosity, thus allowing a faster and uniform perfusion of the graft.

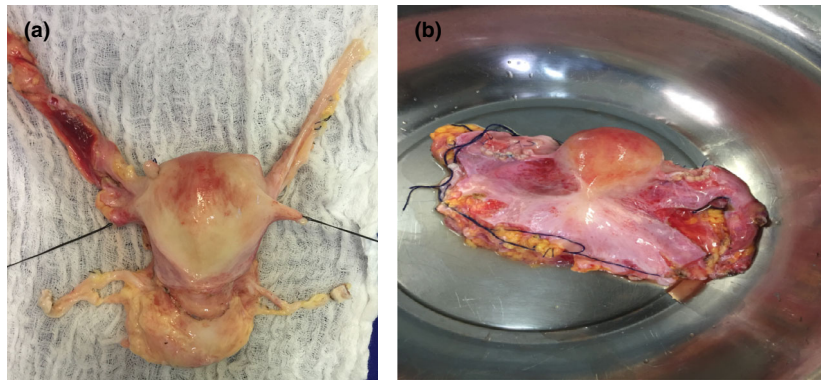


Figure 4 (a) Third procured uterus; (b) organ of donor 7, used for transplantation.

The uterus is a nonvital organ and, to date, a standard protocol for its removal in the sequence of multi-organ procurement has not been established. The time taken to prepare its excision (warm phase) could delay the removal of the other organs, but there was no repercussion on the transplant of the other procured organs. The uterus was the last organ to be removed; nonetheless, it should definitely be retrieved before the removal of the iliac vessels grafts used in the transplantation of the liver and pancreas. To reduce the ischemia time during transplantation from a deceased donor, the team from Dallas, USA, and Turkey decided to remove the uterus before starting the procurement of the other organs, and to perfuse the organ with preservation solution during bench dissection [24,25]. Our team opted to initiate uterine dissection when the warm dissection of the other organs was complete. In case of complications, this order allows rapid cannulation and perfusion of the vital organs.

The transplantation teams were also concerned with the possible contamination of the abdominal cavity after vaginal sectioning. However, in the Dallas experience, the remaining organs were not affected by the previous removal of the uterus [24]. In our experience in Colombia, other organs were removed and transplanted, including two cases in which we used iliac vessels in vascular reconstructions in liver transplant, these procedures were performed by the same team and we had no complication of contamination from vaginal microorganism.

In the description of the technique of uterus removal in the Czech Republic, New York, and Turkey cases, the uterine artery was manipulated [26,27]; however, we finally decided that no manipulation of the uterine pedicle would be done, based on this consideration, it should reduce the risk of vascular injuries that could jeopardize uterine viability.

The largest report of uterus retrieval was performed by the Cleveland team, with 20 cases. They used eight of them for transplant and reported two births [20]. They also do the uterus retrieval after all vital organs harvest, performing inguinal incisions, sectioning ureters on the first steps of surgery, and doing the perfusion cannulating just in one external iliac artery. However, we have some technical differences; we used midline incision; we cut ureters at the moment of uterus retrieval on the cold phase below the external iliac vessel. As we mentioned before, the kidney and liver transplant were done by the same team. Another important difference to mention is that the perfusion was made using both iliac common arteries.

Differences between techniques of uterus retrieval around the world in specific points are shown in Table 3. We could not assure which one was better, but we can see positive outcomes in trials made in Cleveland, Dallas, Brazil, and Czech Republic who performed in 18 transplants using dead donors and achieved five births [18–20]. Perhaps, these different experiences complement each other, and we are convinced that sharing all these experiences will improve future outcomes in this modality of transplant.

Pitfalls and tricks

- Sacral branches of the posterior and anterior divisions of the internal iliac artery were ligated, leaving only the uterine artery patent, this decreased cold ischemia time; nevertheless, this represents a difficult dissection that must be done gently and carefully because of the risk of vascular pelvic injuries and bleeding, which could carry negative impact for other organs.
- Cannulation of both common iliac arteries separately, with perfusion just for pelvis reduced warm ischemia time and allowed homogeneous perfusion of the uterus.

Table 3. Differences between techniques of uterus retrieval around the world.

	Incision	Vascular dissection	Cannulation	Perfusion	Ovaries	Retrieval
D'Amico et al. (2020)	Middle + inguinal	Avoid uterine pedicle dissection	Placed in one external iliac artery	Exclusive for the pelvis	Detached from the utero-ovarian veins during retrieval	After all organs and vascular graft were removed
Testa et al. (2018)	Middle	Avoid uterine pedicle dissection	No cannulation	<i>Ex situ</i> By uterine arteries	Detached from the utero-ovarian veins <i>ex situ</i>	Before other organs were retrieval
Fronek et al. (2016)	No data	Preparation of uterine artery and vein	Placed in two external iliac arteries	No data	No data	After all organs were removed
Gauthier et al. (2014)	Middle + femoral	Avoid uterine pedicle dissection	Placed in two femoral arteries	Same for all abdominal cavity	Detached from the utero-ovarian veins during retrieval	After all organs and vascular graft were removed
Oskan et al. (2013)	Middle	Preparation of uterine artery and vein	<i>Ex situ</i> Placed in two iliac common arteries	<i>Ex situ</i>	No data	Before other organs were retrieval
Del Priore et al. (2007)	Middle	Preparation of uterine artery and vein	Placed in two femoral arteries	Exclusive for the pelvis	Detached from the utero-ovarian veins <i>ex situ</i>	After all organs were removed
Castro et al. (2021)	Middle	Avoid uterine pedicle dissection	Placed in two common iliac arteries	Exclusive for the pelvis	Detached from the utero-ovarian veins <i>ex situ</i>	After all organs were removed

- No manipulation of uterus vascular bundle reduces the possibility of uterine vascular injuries.
- Repairing the vagina makes it easier vaginal section and suturing of the donor's vaginal vault.

The limitations of the present study were as follows: The population was not homogeneous because there were no restrictions to organ procurement and patients who would not be candidates for uterus donation were included (patients 4, 5, 6, 8,11, 13, and 14), as a result of the shortage of organs that meet the inclusion criteria [28]; the technique was being improved throughout the study and surgical times were not measured for all donors, which may compromise the comparison of these parameters in the group as a whole.

We did not adopt any changes in the technique from donor 10 onward, at which point we considered that we had developed the safest method.

This was the first uterine procurement of any kind performed in humans in Latin America, and we consider that this retrieval technique is repeatable and safe. Two uterine transplants were performed using this technique and one of them led to the birth of the first baby in the world from the uterus of a deceased donor. A larger number of patients will allow the refinement of this modality of transplantation, an option that is very important to many women.

Authorship

FC: designed study, performed study, collected data, analyzed data and wrote the paper. DE: designed and performed study. RSP: collected and analyzed data. LD: collected and analyzed data. RMA: collected and analyzed data. LN: collected and analyzed data. DW: collected and analyzed data. RBM: collected and analyzed data. VRS: collected and analyzed data. ECB: contributed important reagents. LACD: contributed important reagents. WA: designed and performed study. HC: collected and analyzed data. GC: collected and analyzed data. JMR: collected and analyzed data. AV: collected and analyzed data.

Funding

The study was supported by the São Paulo Research Foundation (FAPESP) (08/05/2016 process no. 2016/01223-1).

Conflicts of interest

The authors declare no conflicts of interest in this study.

Acknowledgements

The authors would like to thank surgeons and gynecologists of liver transplant groups and Departments of

Gynecology from Hospital das Clinicas and Clinica Imbanaco for their support.

REFERENCES

- Johannesson L, Järholm S. Uterus transplantation: current progress and future prospects. *Int J Womens Health* 2016; **8**: 43.
- Ejzenberg D, Mendes LR, Haddad LB, Baracat EC, D'Albuquerque LA, Andraus W. Uterine transplantation: a systematic review. *Clinics* 2016; **71**: 679.
- Whiteman MK, Kuklina E, Hillis SD, et al. Incidence and determinants of peripartum hysterectomy. *Obstet Gynecol* 2006; **108**: 1486.
- Zhang Y, Yan J, Han Q, et al. Emergency obstetric hysterectomy for life-threatening postpartum hemorrhage: a 12-year review. *Medicine* 2017; **96**: e8443.
- Fageeh W, Raffa H, Jabbar H, Marzouki A. Transplantation of the human uterus. *Int J Gynecol Obstet* 2002; **76**: 245.
- Erman Akar M, Ozkan O, Aydinuraz B, et al. Clinical pregnancy after uterus transplantation. *Fertil Steril* 2013; **100**: 1358.
- Brännström M, Johannesson L, Dahm-Kähler P, et al. First clinical uterus transplantation trial: a six-month report. *Fertil Steril* 2014; **101**: 1228.
- Brännström M, Johannesson L, Bokström H, et al. Livebirth after uterus transplantation. *Lancet* 2015; **385**: 607.
- Brännström M, Bokström H, Dahm-Kähler P, et al. One uterus bridging three generations: first live birth after mother-to-daughter uterus transplantation. *Fertil Steril* 2016; **106**: 261.
- Johannesson L, Kvarnström N, Mölne J, et al. Uterus transplantation trial: 1-year outcome. *Fertil Steril* 2015; **103**: 199.
- Brännström M, Dahm Kähler P, Greite R, Mölne J, Díaz-García C, Tullius SG. Uterus transplantation: a rapidly expanding field. *Transplantation* 2018; **102**: 569.
- Testa G, McKenna GJ, Gunby RT, et al. First live birth after uterus transplantation in the United States. *Am J Transplant* 2018; **18**: 1270.
- Ejzenberg D, Andraus W, Baratelli Carelli Mendes LR, et al. Livebirth after uterus transplantation from a deceased donor in a recipient with uterine infertility. *Lancet* 2019; **392**: 2697.
- Flyckt R, Falcone T, Quintini C, et al. First birth from a deceased donor uterus in the United States: from severe graft rejection to successful cesarean delivery. *Am J Obstet Gynecol* 2020; **223**: 143.
- Brännström M, Dahm-Kähler P. Uterus transplantation and fertility preservation. *Best Pract Res Clin Obstet Gynaecol* 2019; **55**: 109.
- Brännström M, Dahm-Kähler P, Kvarnström N, et al. Live birth after robotic-assisted live donor uterus transplantation. *Acta Obstet Gynecol Scand* 2020; **99**: 1222.
- Jones BP, Saso S, Bracewell-Milnes T, et al. Human uterine transplantation: a review of outcomes from the first 45 cases. *BJOG* 2019; **126**: 1310.
- Johannesson L, Testa G, Putman JM, et al. Twelve live births after uterus transplantation in the Dallas UtErus Transplant Study. *Obstet Gynecol* 2021; **137**: 241.
- Froněk J, Janousek L, Kristek J, et al. Live birth following uterine transplantation from a nulliparous deceased donor. *Transplantation* 2021; **105**: 1077.
- D'Amico G, Quintini C, Egtesad B, et al. Uterus recovery from deceased donor: simple technique securing safety of vital organs and uterus graft. *J Am Coll Surg* 2021; **232**: e1.
- Andraus W, Ejzenberg D, Santos RM, et al. Sheep model for uterine transplantation: the best option before starting a human program. *Clinics* 2017; **72**: 178.
- Wranning CA, Mölne J, El-Akouri RR, Kurlberg G, Brännström M. Short-term ischaemic storage of human uterine myometrium—basic studies towards uterine transplantation. *Hum Reprod* 2005; **20**: 2736.
- Gauthier T, Piver P, Pichon N, et al. Uterus retrieval process from brain dead donors. *Fertil Steril* 2014; **102**: 476.
- Testa G, Anthony T, McKenna GJ, et al. Deceased donor uterus retrieval: a novel technique and workflow. *Am J Transplant* 2018; **18**: 679.
- Ozkan O, Akar ME, Erdogan O, Ozkan O, Hadimioglu N. Uterus transplantation from a deceased donor. *Fertil Steril* 2013; **100**: e41.
- Froněk J, Janousek L, Chmel R. Deceased donor uterus retrieval – the first Czech experience. *Rozhl Chir* 2016; **95**: 312.
- Del Priore G, Stega J, Sieunarine K, Ungar L, Smith JR. Human uterus retrieval from a multi-organ donor. *Obstet Gynecol* 2007; **109**: 101.
- Kristek J, Johannesson L, Testa G, et al. Limited availability of deceased uterus donors: a transatlantic perspective. *Transplantation* 2019; **103**: 2449.