

Expression of WT1 and PAX8 in the epithelial tumours of Malaysian women with ovarian cancer

Anthony Rhodes^a , Narayanan Vallikkannu^b and Pailoor Jayalakshmi^a

^aFaculty of Medicine, Department of Pathology, University of Malaya, Kuala Lumpur, Malaysia; ^bFaculty of Medicine, Department of Obstetrics and Gynaecology, University of Malaya, Kuala Lumpur, Malaysia

ABSTRACT

Background: Ovarian cancer is particularly lethal due to late stage at presentation. The subtypes behave differently with respect to their biology and response to treatment. Two recent markers reported to be useful in assisting in the diagnosis are WT1 and PAX8. Malaysia, with its multi-ethnic population provides an opportunity to study the expression of these biomarkers in ovarian cancer in the three most populous ethnicities in Asia and ascertain their usefulness in the diagnosis of ovarian carcinoma.

Materials and methods: Tissues from ovarian epithelial neoplasms diagnosed between 2004 and 2012 were tested using antibodies to WT1 and PAX8. The slides were assessed to determine levels of marker expression and related to ethnicity, ovarian tumour type, grade and stage.

Results: Serous tumours were the main histological type ($n = 44$), the remaining being endometrioid ($n = 15$), mucinous ($n = 15$) and clear cell tumours ($n = 7$). Late stage at diagnosis was significantly associated with serous ($p < 0.001$) and endometrioid ($p = 0.026$) tumours. The vast majority of serous tumours were positive for WT1 (87%, $p < 0.001$) and PAX8 expression (86%, $p < 0.001$) whilst 40% of endometrioid tumours were positive for PAX8 and 13% for WT1. Few mucinous carcinomas ($n = 1$) and clear cell carcinomas ($n = 2$) expressed PAX8, and none expressed WT1. There was no significant difference in the tumour expression of either WT1 or PAX8 between the three Malaysian ethnicities.

Conclusions: In an Asian setting, PAX8 and WT1 are expressed in the vast majority of serous ovarian cancers and may be useful in distinguishing serous ovarian carcinomas from other poorly differentiated tumours.

ARTICLE HISTORY

Received 7 June 2016
Accepted 18 July 2016

KEYWORDS

WT1; PAX8; ovarian cancer; Asia

Introduction

In the developed World, ovarian cancer is the fourth most common cause of female-related cancer deaths. [1] It is a particularly lethal cancer compared to other gynaecological cancers, as women usually present at an advanced stage due to lack of early clinical symptoms. Consequently, the median 10-year survival rate for patients, even when treated at major treatment centres, is only 40–50%. [1] In Malaysia, ovarian cancer is the fourth commonest cancer in women. [2] However, it is the third most common malignancy in Malay Malaysian women, second only to breast and colorectal cancer and accounting for 8% of all cancers in this ethnic group. In comparison, it is less common in Malaysian Chinese and Malaysian Indian women where it is the fifth most common cancer, and accounts for 5–6% of all cancers. [2] The reason for these differences in the occurrence of ovarian cancer between the ethnic groups is not known.

The vast majority of ovarian cancers arise from the epithelial surface of the ovary and the rest from germ

cells or stromal cells. [1] The epithelial cancers are further classified by their histological appearance as; serous carcinoma (30–70%), endometrioid adenocarcinoma (10–20%), mucinous adenocarcinoma (5–20%), clear cell carcinoma (3–10%) and undifferentiated (1%). [3] The serous and undifferentiated types have the worst prognosis with a 5-year survival ranging from 11 to 35%, whilst the other types have significantly better 5-year survival rates, ranging from 35 to 69%. [4,5] The subtypes behave differently with respect to their biology and response to treatment. [3] In addition, they can be difficult to diagnose from metastatic spread from other organs in the peritoneal cavity. [6] Consequently, the use of reliable immunohistochemical markers to assist in this differentiation can be valuable. Two recent markers reported to be useful in this respect are WT1 and PAX8. [6–10] (Figure 1)

The importance of the Wilms Tumour 1 (WT1) gene was originally discovered in relation to a rare tumour of the kidney termed a nephroblastoma and later the term Wilm's Tumour was used for this malignancy, in which

the WT1 gene is mutated.[10] It was subsequently identified as a tumour suppressor gene responsible for the coding of transcription factors important in cell growth and differentiation, particularly of the kidney, ovary and testes.[11] WT1 is required for the structural and functional development of the gonads and has found to be highly expressed in primary and primordial ovarian follicles. It is expressed in the surface epithelium of the normal mature ovary and in stromal and granulosa cells. [10] Studies to date show that in epithelial cancers of the ovary, WT1 is mainly expressed in the serous subtype.[12]

PAX8 is a member of a family of 9 genes (PAX1-PAX9) whose transcription factors play a critical role in the formation of tissues and organs during embryonic development, and in particular in thyroid, renal and Müllerian cell differentiation.[13,14] In ovarian epithelial cancers, it has been found to be mainly expressed in the serous, clear cell and endometrioid subtypes.[9]

To date there have been relatively few studies that have investigated the expression of WT1 and PAX8 in Asian women with ovarian cancer, though a recent study on southern Thai women with ovarian cancer showed the expression of WT1 to be significantly lower than reported in western cohorts, with only half of the serous carcinomas expressing WT1.[15] With WT1 and PAX8 being increasingly used in clinical practice to assist in the diagnosis and typing of ovarian cancer, it is important to determine its usefulness in an Asian setting. The aims of the current study were to investigate the expression of PAX8 and WT1 in a cohort of Malaysian women of different ethnicities attending the same medical centre and to ascertain whether biomarker expression was similar to that reported from other parts of the World and therefore a useful adjunct for use in the diagnosis of ovarian carcinoma.

Materials and methods

Clinical data on patient age, ethnicity and stage were extracted from the departments' database for this series of cases. All accessible histologically diagnosed primary ovarian epithelial neoplasms between 1 January 2004 to 31 December 2012 at the Department of Pathology, University of Malaya Medical Centre were retrieved, and the slides reviewed. All tissues had been fixed in 10% neutral-buffered formalin for 6 to 72 h and processed to paraffin wax blocks, from which sections were cut at 3- μ m thickness on a rotary microtome and mounted onto charged glass slides to ensure maximum adhesion.

Serous tumours were graded as either high or low grade, [16]. Using the FIGO system recommended for the grading of endometrioid adenocarcinomas, ovarian endometrioid and mucinous carcinomas were graded as I, II or III depending on whether they were well, moderately or poorly differentiated, respectively.[17] Clear cell ovarian carcinomas were automatically graded as high grade.[12]

Expression of PAX8 and WT1 was tested using standard immunohistochemical methods. Briefly, slides were placed on a Ventana Benchmark XT1 Instrument (Ventana Medical Systems Inc, Tucson, USA) and stained using 'ready to use' primary antibodies to PAX8 (clone MRQ-50, Cell Marque, Rocklin, CA, USA) and WT1 (clone 6F-H2, Cell Marque). Antigen retrieval employed the CC1 standard step on the Ventana instrument for 32 min and detection was achieved with a horse radish peroxidase (HRP) label and DAB chromogen (OptiView DAB Detection Kit, Ventana Medical Systems).

Tissue sections of renal cortex were used as a positive control for both WT1 and PAX8 immunostaining.

Assessment of staining for both PAX8 and WT1 was carried out by multiplying the percentage of cells with a numeric score, with a maximum possible total score of 300.[18] The percentages were determined by estimating the number of cells which showed positive nuclear staining for PAX8 or WT1 in the tumour compartment, when examined microscopically. The numeric score was given as follows; score '0' no staining; score 1 weak nuclear staining; score 2 medium intensity nuclear staining; score 3 strong intense nuclear staining. Using this system, a total score of 50 and above was used to define a positive result for PAX8 and WT1.

Statistical analysis

The continuous variables involving age were described using means and compared using the Student *T*-Test. Categorical variables (ethnicity, stage, grade, PAX8 and WT1 staining) were expressed as proportions and compared using either the Chi-squared test or the one sample binomial test. *P* values of less than 0.05 were considered statistically significant. All statistical analyses were carried out using IBM Statistics software (version 22, IBM SPSS, Armonk, NY).

Results

The mean age of the 81 patients recruited to the study was 53 years (IQR, 46-60), of which a significant proportion were of Malay ethnic origin ($n = 46$, 57%, $p < 0.01$), compared to Chinese ($n = 20$, 25%) and Indian ($n = 15$, 19%). Malignant serous tumours were the main histological type, accounting for over half of all cases ($n = 44$), the remaining types were endometrioid ($n = 15$) – four of which had synchronous adenocarcinoma of the ovary, mucinous ($n = 15$), and clear cell ($n = 7$). Serous and endometrioid tumours were significantly associated with late stage disease, compared to mucinous carcinomas (Table 1). The three ethnic groups did not differ significantly with respect to the histological type of ovarian tumour (Table 2).

WT1 and PAX8 expression

There was no significant difference in the tumour expression of either WT1 or PAX8 between the three Malaysian

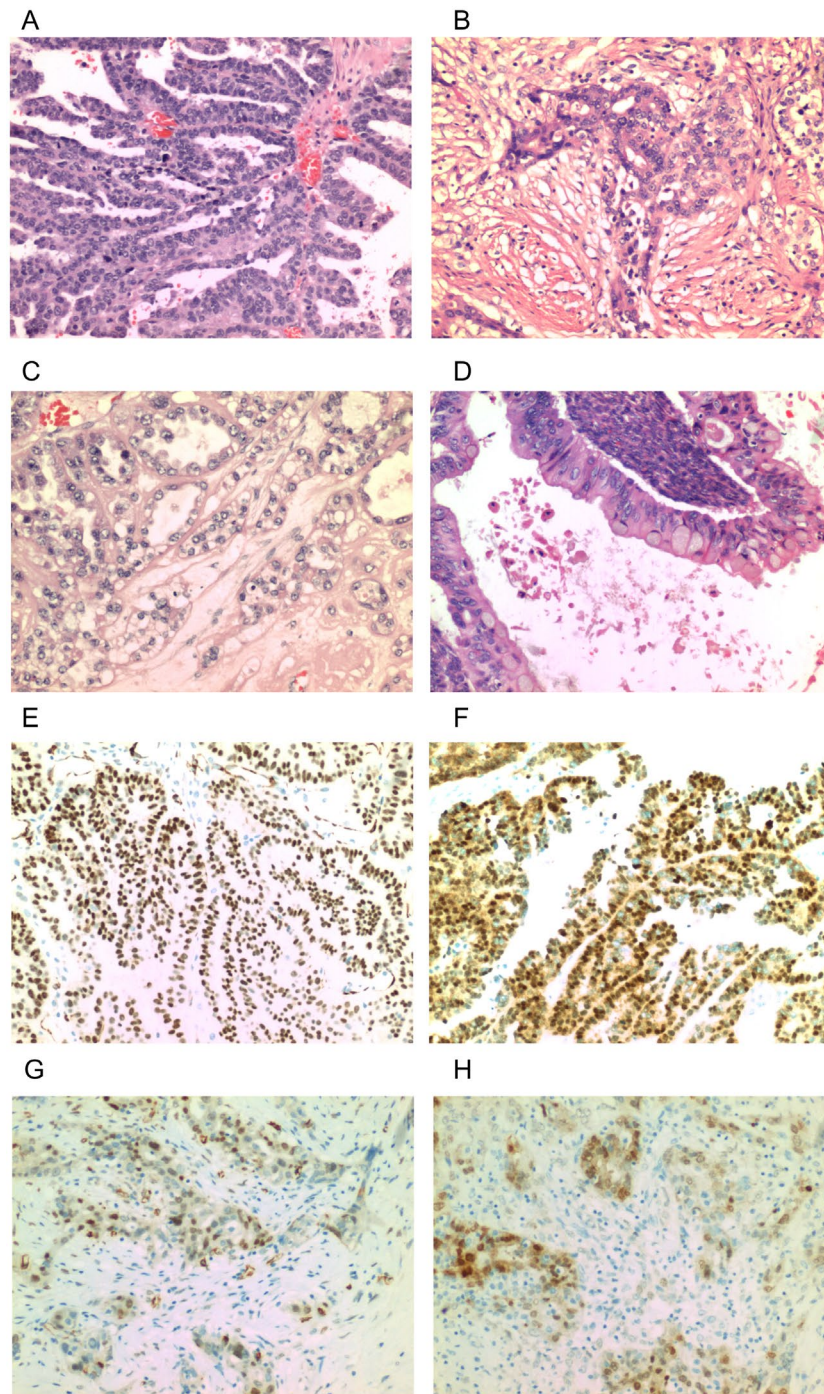


Figure 1. Haematoxylin and Eosin staining of the four types of ovarian cancer investigated; serous carcinoma showing characteristic glandular structures with papillary processes (A), endometrioid adenocarcinoma with glandular structures resembling endometrial glands (B), clear cell carcinoma with glands lined by cells with a clear cytoplasm and a characteristic 'hobnail' appearance (C) and mucinous adenocarcinoma with glands lined by mucin secreting tall columnar epithelium (D). Immunohistochemical staining of WT1 and PAX8, respectively, in serous (E, F) and endometrioid (G, H) cancers. Magnification, $\times 100$.

ethnicities (Table 3). There was a strong association between PAX8 and WT1 expression, with 67 (83%) of tumours exhibiting similar expression for both markers ($p < 0.001$). The vast majority of serous tumours were positive for both WT1 (39/44, 87%, $p < 0.001$) and PAX8 expression (38/44, 86%, $p < 0.001$). In comparison, 6/15 (40%) of endometrioid tumours were positive for PAX8 and 2/15 (13%) positive for WT1. Very few mucinous carcinomas

and clear cell carcinomas expressed PAX8, and none expressed WT1 (Table 3). WT1 and PAX8 expression were not associated with pathological grade or stage in either the serous or endometrioid tumours (Tables 4 and 5). WT1 staining showed 95% specificity and 89% sensitivity for the staining of serous ovarian tumours, whilst, PAX8 showed 76% specificity and 86% sensitivity for this subtype.

Table 1. Pathological stage in relation to histological subtype of ovarian cancer.

Histological type	Stage				Total	P for χ^2 test
	I	II	III	IV		
Serous	5	4	30	5	44	<0.001
Endometrioid	5	1	8	1	15	0.026
Mucinous	11	1	2	1	15	<0.001
Clear cell	3		4		7	1.000 ^a

^aCompared using the one sample binomial test.**Table 2.** Ethnicity and histological subtype of ovarian cancer.

Histological type	Ethnic group			Total	P for χ^2 test
	Chinese	Malay	Indian		
Serous	12	22	10	42	0.540
Endometrioid	2	11	2	18	
Mucinous	3	9	3	15	
Clear cell	3	4	0	7	

Table 3. Factors associated with PAX8 expression WT1 expression.

	Overall	PAX8 positive (%)	PAX8 negative (%)	P for χ^2 test
<i>PAX8 expression</i>				
No. of patients	81	47(58)	34(42)	
Age (mean, years)	53	53	52	0.737 ^a
Ethnicity, N (%)				0.688
Chinese	20 (25)	12 (26)	8 (24)	
Malay	46 (57)	25 (53)	21 (62)	
Indian	15 (19)	10 (21)	5 (15)	
Tumour type, N (%)				<0.001
Serous	44(54)	38(81)	6(18)	
Endometrioid	15(19)	6(13)	9(27)	
Mucinous	15(19)	1(2)	14(41)	
Clear Cell	7(9)	2(4)	5(15)	
<i>WT1 expression, N (%)</i>				
WT1 positive	41(51)	37(79)	4(12)	<0.001
WT1 negative	40(49)	10(21)	30(88)	
	Overall	WT1 positive (%)	WT1 negative (%)	P for χ^2 test
<i>WT1 expression</i>				
No. of patients	81	41	40	
Age (mean, years)	53	53	52	0.678 ^a
Ethnicity, N (%)				0.133
Chinese	20 (25)	10 (24)	10 (25)	
Malay	46 (57)	20 (49)	26 (65)	
Indian	15 (19)	11 (27)	4 (10)	
Tumour type, N (%)				<0.001
Serous	44(54)	39(95)	5(13)	
Endometrioid	15(19)	2(5)	13(33)	
Mucinous	15(19)	0(0)	15(38)	
Clear cell	7(9)	0(0)	7(18)	
<i>PAX8 expression, N (%)</i>				
PAX8 positive	47(58)	37(90)	10(25)	<0.001
PAX8 negative	34(42)	4(10)	30(75)	

^aCompared using T-test.**Table 4.** Ovarian cancer type, grade and WT1 and PAX8 expression.

Type ^a	Grade	WT1 negative	WT1 positive	P for χ^2 test ^a	PAX8 negative	PAX8 positive	P for χ^2 test
Serous (n = 44)	Low	0	4	0.606	0	4	0.544
	High	5	35		6	34	
Endometrioid (n = 15)	1	6	0	0.098	5	1	0.158
	2	6	1		3	4	
	3	1	1		1	1	

^aBoth mucinous and clear cell types were excluded from this analysis as they were all well differentiated or of high grade, respectively.

Table 5. Ovarian cancer type, stage and WT1 and PAX8 expression in relation to tumour stage in serous and endometrioid ovarian cancer.

Type ^a	Stage	WT1 negative	WT1 positive	<i>P</i> for χ^2 test ^a	PAX8 negative	PAX8 positive	<i>P</i> for χ^2 test
Serous (<i>n</i> = 44)	I	0	5	0.272	0	5	0.352
	II	1	3		1	3	
	III	4	26		4	26	
	IV	0	5		1	4	
Endometrioid (<i>n</i> = 15)	I	4	1	0.459	3	2	0.267
	II	1	0		1	0	
	III	7	1		5	3	
	IV	1	0		0	1	

^aBoth mucinous and clear cell types were excluded from this analysis as all were negative for WT1 expression and the majority negative for PAX8 expression.

Discussion

This is the first study to compare the expression of both PAX8 and WT1 in South-East Asian women with ovarian cancer. Ovarian cancer is the fourth most common malignancy affecting Malaysian women, though the third most common in the Malay ethnic group.[2] These differences cannot be completely explained by population demographics or socio-economic reasons, and warrant further investigation.

As seen with western studies, the serous subtype was the most common type of ovarian tumour.[3] With respect to PAX8 and WT1, there was no significant difference in tumour expression of these markers between the three main Malaysian ethnic groups. Similarly, there was no difference in the proportion of histological types in each ethnic group. PAX8 and WT1 were highly expressed in ovarian serous carcinomas, with 87% of cases positive for WT1 and 86% for PAX8. In comparison, WT1 was not expressed in any of the mucinous carcinomas and only one of these tumours was positive for PAX8. Consequently, this study shows that in Asian women with ovarian cancer almost all the serous subtypes are positive for PAX8 and WT1, in contrast to the mucinous and clear cell types, very few of which express these markers. In particular, WT1 was only expressed in 2 of the cases of the endometrioid subtype and none of the clear cell or mucinous tumours. The numbers of clear cell carcinomas investigated were low due to the rarity of this subtype, though were similar in number to that seen with other studies.[6,7,9,10,19,20] With this in mind, we confirm the value of WT1, in particular, in helping distinguish serous carcinoma from other poorly differentiated carcinomas.

A recent study showed WT1 expression to be only positive in approximately half of a cohort of women in southern Thailand with serous ovarian carcinomas [15]. In contrast, we report figures similar to that seen in other parts of the World with the vast majority of serous carcinomas positive for both PAX8 and WT1. Historically, the origins and genetic profile of the majority of the southern Thais are similar to that of the Malaysian Malays.[21] We therefore further analysed our data for the expression of WT1 and PAX8 in the serous ovarian cancers of just the Malay patients. Interestingly, the results are similar to that which we obtained for the whole cohort, with 19/22 (86%) expressing WT1 and 20/22 (91%) expressing PAX8 in their tumours. Clearly, therefore either methodological

differences account for the contrasting results between our study and that of Netinatsunthorn et al. [15], or environmental and lifestyle factors currently unknown play a significant role and require further investigation.

Serous and endometrioid cancers were significantly associated with late stage disease, compared to mucinous carcinomas, which were significantly associated with stage I disease. Expression of WT1 and PAX8 in the serous and endometrioid subtypes was not associated with grade or stage, though this is inconclusive due to the small number of cases, and the majority being high grade and late stage, respectively. However, typically the majority of both low- and high-grade serous carcinomas express WT1.[12] All mucinous and clear cell carcinomas are usually well differentiated or high grade, respectively.

It is now generally accepted that low- and high-grade serous carcinomas comprise two different tumours with differing underlying molecular pathways, pathogenesis, behaviour and prognosis.[12] As seen in the current study, high-grade serous carcinoma is considerably more common than low grade. With respect to molecular markers other than PAX8 and WT1, high-grade serous carcinomas are more likely to be positive for; p53, bcl-2, HER2, HLA-G and p16, than low-grade serous carcinoma.[22,23] Similarly, high-grade serous carcinomas have a significantly higher proliferative index as determined by positivity for Ki67 than low-grade serous carcinomas, reflecting the abundant mitotic activity of these tumours.[12] With respect to the molecular pathways involved, low-grade serous carcinomas are associated with BRAF mutations in the majority of cases, in contrast high-grade serous carcinomas do not usually have these mutations [24–26]. The majority of both low- and high-grade serous carcinomas are at a late stage when diagnosed (Stage III or IV) and therefore carry a relatively poor prognosis compared to other gynaecological cancers. Of the few studies that have compared survival in low- and high-grade serous carcinomas, the median survival is significantly less in the high-grade tumours.[16,27]

In summary, WT1 and PAX8 are expressed in the vast majority of serous ovarian cancers but in only one mucinous adenocarcinoma. This work represents an advance in biomedical science because it confirms the value of testing for PAX8 and WT1, for determining the diagnosis of ovarian cancer in Asian women.

Summary table

What is known about this subject:

- Ovarian cancer is particularly lethal due to late stage at presentation, with a median 10-year survival rate of 40–50%.
- Serous ovarian cancer has the worst prognosis compared to the other subtypes.
- WT1 and PAX8 are transcription factors that play important roles in the formation of tissues and organs during embryonic development.

What this paper adds:

- WT1 and PAX8 are expressed in the majority of serous tumours of Malaysian women with ovarian cancer.
- WT1 and PAX8 are useful immunohistochemical markers to assist in the diagnosis of ovarian cancer in an Asian setting.

Disclosure statement

No potential conflict of interest was reported by the authors.

Funding

This study was approved by the medical ethics committee of the University of Malaya Medical Centre and supported by the research [grant number UMRG-RG398-12HTM].

ORCID

Anthony Rhodes  <http://orcid.org/0000-0002-1187-0939>

References

- [1] Jayson GC, Kohn EC, Kitchener HC. Ovarian cancer. *Lancet*. 2014;384:1376–1388.
- [2] Malaysian National Cancer Registry. Malaysian cancer statistics: data and figures. Putra Jaya (Malaysia): Ministry of Health; 2007. Available from: http://www.care.upm.edu.my/dokumen/13603_NCR2007.pdf. [Cited 2016 Jun 4].
- [3] Rosen DG, Yang G, Liu G, et al. Ovarian cancer: pathology, biology and disease models. *Front. Biosci.* 2010;14:2089–2102.
- [4] Björkholm E, Pettersson F, Einhorn N, et al. Long-term follow-up and prognostic factors in ovarian carcinoma: the Radiumhemmet series 1958 to 1973. *Acta Radiol. Oncol.* 1982;21:413–419.
- [5] Högberg T, Carstensen J, Simonsen E, et al. Treatment results and prognostic factors in a population-based study of epithelial ovarian cancer. *Gynecol. Oncol.* 1993;48:38–49.
- [6] Zhao L, Guo M, Sneige N, et al. Value of PAX8 and WT1 immunostaining in confirming the ovarian origin of metastatic carcinoma in serous effusion specimens. *Am. J. Clin. Pathol.* 2012;137:304–309.
- [7] Tacha D, Zhou D, Cheng L. Expression of PAX8 in normal and neoplastic tissues. *Appl. Immunohistochem. Mol. Morphol.* 2011;19:293–299.
- [8] Al-Hussaini M, Stockman A, Foster H, et al. WT-1 assists in distinguishing ovarian from uterine serous carcinoma and in distinguishing between serous and endometrioid ovarian carcinoma. *Histopathology.* 2004;44:109–115.
- [9] Laury AR, Perets R, Piao H, et al. A comprehensive analysis of PAX8 expression in human epithelial tumors. *Am. J. Surg. Pathol.* 2011;35:816–826.
- [10] Liliac L, Carcangiu ML, Canevari S, et al. The value of PAX8 and WT1 molecules in ovarian cancer diagnosis. *Rom. J. Morphol. Embryol.* 2013;54:17–27.
- [11] Gessler M, Poustka AM, Cavenee W, et al. Homozygous deletion in Wilms tumours of a zinc-finger gene identified by chromosome jumping. *Nature.* 1990;343:774–778.
- [12] McCluggage WG. Morphological subtypes of ovarian carcinoma: a review with emphasis on new developments and pathogenesis. *Pathology.* 2011;43:420–432.
- [13] Plachov D, Chowdhury K, Walther C, et al. PAX8, a murine paired box gene expressed in the developing excretory system and thyroid gland. *Development.* 1990;110:643–651.
- [14] Poleev A, Fickenscher H, Mundlos S, et al. PAX8, a human paired box gene: isolation and expression in developing thyroid, kidney and Wilms' tumors. *Development.* 1992;116:611–623.
- [15] Netinatsunthorn W, Hanprasertpong J, Dechsukhum C, et al. WT1 gene expression as a prognostic marker in advanced serous epithelial ovarian carcinoma: an immunohistochemical study. *BMC Cancer.* 2006;6:51. doi: <http://dx.doi.org/10.1186/1471-2407-6-90>
- [16] Malpica A, Deavers MT, Lu K, et al. Grading ovarian serous carcinoma using a two-tier system. *Am. J. Surg. Pathol.* 2004;28:496–504.
- [17] McCluggage WG, Judge MJ, Clarke BA, et al. Data set for reporting of ovary, fallopian tube and primary peritoneal carcinoma: recommendations from the International Collaboration on Cancer Reporting (ICCR). *Mod. Pathol.* 2015;28:1101–1122.
- [18] Devan SM, Pailoor J, Sthaneshwar P, et al. Pattern of tissue expression of CA-125 and HE4 in primary epithelial ovarian tumours and correlation with serum CA-125 levels. *Asian Pac. J. Cancer Prev.* 2013;14:4545–4548.
- [19] Shimizu M, Toki T, Takagi Y, et al. Immunohistochemical detection of the Wilms' tumor gene (WT1) in epithelial ovarian tumors. *Int. J. Gynecol. Pathol.* 2000;19:158–163.
- [20] McCluggage WG. WT1 is of value in ascertaining the site of origin of serous carcinomas within the female genital tract. *Int. J. Gynecol. Pathol.* 2004;23:97–99.
- [21] Kutanan W, Kitpipit T, Phetpeng S, et al. Forensic STR loci reveal common genetic ancestry of the Thai-Malay muslims and Thai Buddhists in the deep southern region of Thailand. *J. Human Genet.* 2014;59:675–681.
- [22] O'Neill CJ, McBride HA, Connolly LE, et al. High-grade ovarian serous carcinoma exhibits significantly higher p16 expression than low-grade serous carcinoma and serous borderline tumour. *Histopathology.* 2007;50:773–779.
- [23] O'Neill CJ, Deavers MT, Malpica A, et al. An immunohistochemical comparison between low-grade and high-grade ovarian serous carcinomas. Significantly higher expression of p53, MIB1, bcl2, her-2/neu and C-KIT in high-grade neoplasms. *Am. J. Surg. Pathol.* 2005;29:1034–1041.
- [24] Singer G, Shih IM, Truskinovsky A, et al. Mutational analysis of k-ras segregates ovarian serous carcinomas into two types: invasive MPSC (low-grade tumor) and conventional serous carcinoma (high-grade tumor). *Int. J. Gynecol. Pathol.* 2003;22:37–41.
- [25] Sieben NLG, Macropoulos P, Roemen GMJM, et al. In ovarian neoplasms, BRAF, but not KRAS, mutations are restricted to low-grade serous tumours. *J. Pathol.* 2004;202:336–340.
- [26] Vang R, Shih IM, Kurman RJ. Ovarian low-grade and high-grade serous carcinoma. *Adv. Anat. Pathol.* 2009;16:267–282.
- [27] Gershenson DM, Sun CC, Lu KH, et al. Clinical behavior of stage II-IV low-grade serous carcinoma of the ovary. *Obstet. Gynecol.* 2006;108:361–368.