


Successful treatment of severe cholinergic urticaria with omalizumab: A case report

Aoi Yamasaki MD¹ | Yoshiko Oda MD² | Hideaki Tanizaki MD, PhD¹ |
Toshihiro Otsuka MD¹ | Atsushi Fukunaga MD, PhD² | Chikako Nishigori MD, PhD² |
Shinichi Moriwaki MD, PhD¹ 

¹Department of Dermatology, Osaka Medical College, Takatsuki, Japan

²Division of Dermatology, Department of Internal Related, Kobe University Graduate School of Medicine, Kobe, Japan

Correspondence

Shinichi Moriwaki, Department of Dermatology, Osaka Medical College, Takatsuki, Osaka, Japan.
Email: der002@osaka-med.ac.jp

Abstract

Omalizumab, a humanized anti-IgE monoclonal antibody, has been approved in Japan for the treatment of antihistamine-resistant idiopathic chronic spontaneous urticaria. We herein report a 27-year-old Japanese woman suffering from a 2-year history of severe cholinergic urticaria (sweat allergy-type), which was unresponsive to various H₂-antihistamines and other medication but was successfully treated with omalizumab. The patient showed rapid and marked reduction in her symptoms of urticaria after the first injection of omalizumab (300 mg). She has been receiving omalizumab treatment quaque 4 weeks (q4w) three times and subsequent q6w six times, followed by maintenance treatment q8w without any adverse reactions for a total of 68 weeks. Although further large-scale clinical investigation is needed, omalizumab may be a beneficial therapeutic remedy for patients with intractable, chronic inducible urticaria including cholinergic urticaria.

KEYWORDS

cholinergic urticaria, chronic inducible urticaria, omalizumab, sweat allergy

1 | INTRODUCTION

In 2017, omalizumab (Xolair[®]), a monoclonal antibody targeting the high-affinity receptor binding site on human IgE, was approved for the treatment of antihistamine-resistant idiopathic chronic urticaria. This followed its approval in 2009 for the treatment of refractory severe asthma resistant to former therapies in Japan. Albeit only in sporadic cases, omalizumab had also been reported to be beneficial for several types of chronic inducible urticaria such as cholinergic urticaria and solar urticaria, although the underlying mechanism how it exerts its action on these conditions was unclear.¹⁻³ We herein report a patient with severe cholinergic urticaria, which was unresponsive to various antihistamines with high doses and several other treatments including leukotriene receptor antagonists and

H₂-antihistamines. Omalizumab showed a rapid, remarkable, and continuous efficacy on the symptoms of the disease without any deleterious events.

2 | CASE REPORT

A 27-year-old Japanese woman presented to our department with a 2-year history of pruritic pinpoint wheals with surrounding erythema, which were induced by heat, exercise, hot baths, and emotional upset. She had atopic dermatitis in her infancy. Before her referral, the patient had been treated with fexofenadine 360 mg/d, loratadine 20 mg/d, famotidine 20 mg/d, tranexamic acid 1500 mg/d, and montelukast 20 mg/d without therapeutic effects. She noticed that

This is an open access article under the terms of the Creative Commons Attribution-NonCommercial License, which permits use, distribution and reproduction in any medium, provided the original work is properly cited and is not used for commercial purposes.

© 2019 The Authors. *Journal of Cutaneous Immunology and Allergy* published by John Wiley & Sons Australia, Ltd on behalf of The Japanese Society for Cutaneous Immunology and Allergy

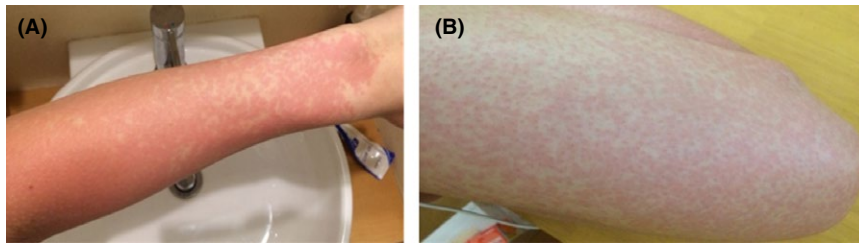


FIGURE 1 Approximately 15 min after taking a hot bath, severe pruritic wheals appeared on the patient's skin especially at the extremities A, left forearm, B, left thigh

pruritic pinpoint and/or coalesced wheals, especially on the extremities, usually appeared approximately 15 minutes after taking a hot bath (Figure 1). The urticaria control test (UCT) score was 0 at this time. A general laboratory examination of the blood and urine of the patient revealed no abnormalities with all values within the normal limits, including the liver function and antinuclear antibodies; while the total values of serum IgE and TARC were 241 IU/mL and 48 pg/mL, respectively, the allergen-specific IgE grades were house dust mite (3+), house dust (3+), dog (3+), cedar pollen (2+), and cypress pollen (2+). The Allerport[®] histamine release test revealed (3+) positivity for human sweat antigen. The satellite urticarial response was induced by intradermal injection of acetylcholine (Ovisot[®]), and sweating points appeared in accordance with satellite urticarial lesions by the modified Minor method (Figure 2). No urticarial reactions were induced by intradermal injection of noradrenaline or normal saline. Basophil activation test revealed that upregulation of CD203 on basophils was observed by stimulating unpurified sweat antigen up to 100 folds dilution (Figure 3). Based on the clinical features and the findings of these provocation tests, we diagnosed the condition as sweat allergy-type cholinergic urticaria.

She was subsequently prescribed bepotastine besilate 40 mg/d and lafutidine 20 mg/d; however, the UCT score was still eight despite the administration of these medications, indicating poor control. At this point, we decided to administer subcutaneous omalizumab (300 mg) every 4 weeks (q4w). Three days after the first injection, she was free from all symptoms. In addition, the doses of her concomitant medications were able to be reduced to bepotastine besilate 20 mg/d and lafutidine 10 mg/d without inducing any symptoms relapses. Her condition continued to improve and achieved the UCT score: 16, and the interval of omalizumab injection was

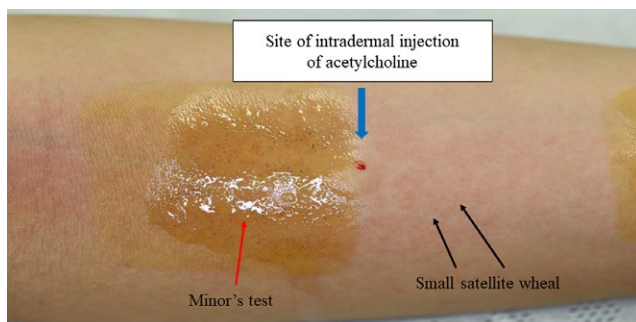


FIGURE 2 Both the satellite urticarial response induced by intradermal acetylcholine (Ovisot[®]) and sweating points appearing in accordance with satellite urticarial lesions by the modified Minor method were observed

extended to 6 weeks after three courses of q4w injections. At week 20, the patient stopped all concomitant medication and has been free from any symptoms thereafter; she has now resumed all activities, including hot baths and extensive workouts under medication with omalizumab. In summary, she has been receiving omalizumab treatment three times q4w and six times q6w, followed by maintenance treatment q8w without any adverse reactions for a total of 68 weeks (Figure 4).

3 | DISCUSSION

Cholinergic urticaria, which was first described by Duke in 1924, is a physical urticaria, characterized by pinpoint-sized wheals surrounded by erythema with severe pruritus, which were induced by physical stimuli such as an increase in body temperature, passive warming (eg, a hot bath), physical exercise, and emotional stress.⁴ Although these symptoms usually subside within several hours, the episodes appear often in daily life, and most such patients complain of serious stinging, tingling pain, and itching during the onset of symptoms, resulting in a tremendous disturbance to their quality of life.⁵ Severe symptoms such as angioedema, respiratory symptoms, and anaphylaxis sometimes accompanied with urticarial symptoms.⁶ Although the precise mechanism underlying the induction of whealing remains unclear, the involvement of acetylcholine, poral occlusion, cholinergic receptor M3 abnormalities, sweat allergy, effects of unknown serum factors, and dyshidrosis has been reported.⁴ Fukunaga et al proposed that there are four subtypes of cholinergic urticaria based on the pathogenesis and clinical characteristics of this condition: (a) sweat allergy-type, (b) follicular-type with a positive autologous serum skin test result, (c) type with palpebral angioedema, and (d) type with acquired anhidrosis and/or hypohidrosis.^{7,8} In our case, the patient was diagnosed with sweat allergy-type which is the most common type of cholinergic urticaria.

Antihistamines, acting on blocking histamine H1 receptors, are the first-line therapy for patients with cholinergic urticarial. However, the present case showed only a limited response to the standard dose of antihistamines. Increasing the dose of antihistamines and the addition of other agents did not improve urticaria symptoms. Several studies have shown that omalizumab, a biologics containing humanized monoclonal anti-IgE antibody, was effective for treating severe cholinergic urticaria.^{9,10} Therefore, we decided to treat our patient with the agent. Omalizumab acts by

FIGURE 3 In the basophil activation test, upregulation of CD203 was confirmed from basophils by stimulation with diluted crude sweat at 0.01, 0.1, and 0.3 $\mu\text{g}/\text{mL}$. The Allergen Kit (Beckman Coulter, Fullerton, CA) was used for the quantification of basophil CD203c expression. This assay was performed within 24 h after whole blood sampling. In brief, we used crude sweat and anti-IgE antibody (clone; E124-2-8D) as a positive control and phosphate-buffered saline as a negative control. The crude sweat collected from one AD patient and diluted in PBS to final concentrations at 0.001, 0.01, 0.1, and 0.3 $\mu\text{g}/\text{mL}$

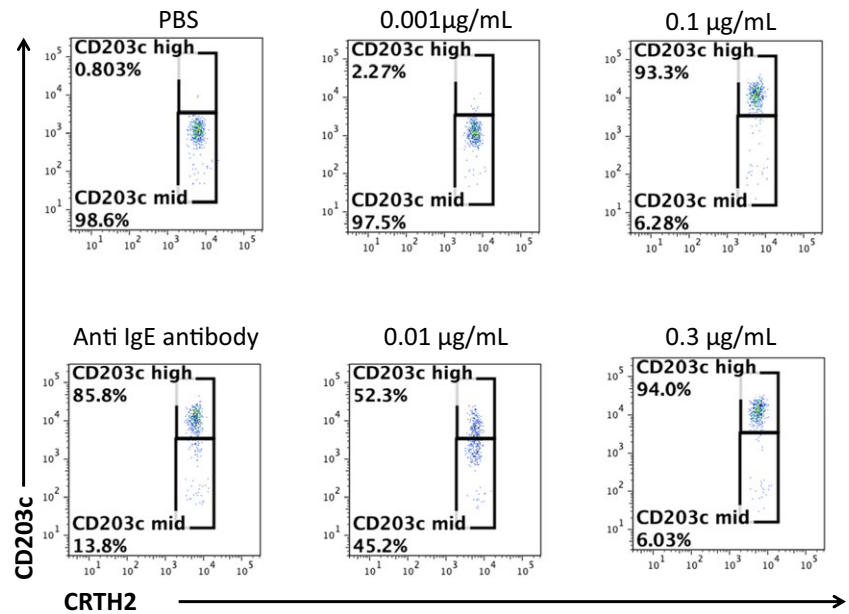
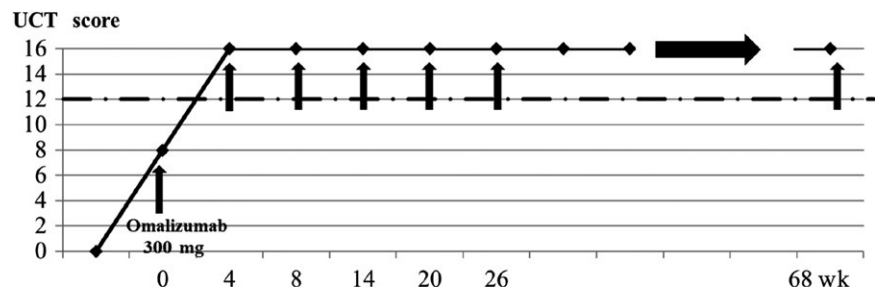


FIGURE 4 Omalizumab treatment resulted in the rapid and marked reduction in symptoms of cholinergic urticaria. The black arrows indicate the time points of omalizumab shots



binding free IgE at the site where IgE would bind to its high-affinity receptor (Fc ϵ RI) and low-affinity receptor (Fc ϵ RII) in mast cells and basophils, thereby reducing the level of free IgE in the serum.¹¹ In addition, by reducing the level of free IgE, the expression of Fc ϵ RI and Fc ϵ RII on mast cells is downregulated.¹¹ Most recently, MGL-1304 of *Malassezia globosae*, a major allergen in the sweat of patients with atopic dermatitis, was suggested to be an important antigen in the majority of patients with cholinergic urticarial as well.¹² Another study reported that the level of MGL-1304-specific IgE in the sera of patients with cholinergic urticaria was significantly higher than in normal individuals.¹³ In our case, omalizumab may have acted by binding a sweat antigen-specific IgE, such as MGL-1304-specific IgE, thereby preventing it from binding to its receptors (Fc ϵ RI and Fc ϵ RII). As a consequence, the release of histamines strongly related to the patient's symptoms, from mast cells and basophils was likely to be markedly reduced. The secondary effect of omalizumab in downregulating the expressions of Fc ϵ RI and Fc ϵ RII in basophils and mast cells raises the possibility of omalizumab being effective against other types of cholinergic urticaria than the sweat allergy-type, although there is as yet no clear evidence for its efficacy against the type of acquired idiopathic generalized anhidrosis (AIGA).^{14,15}

Chronic inducible urticaria, including cholinergic urticaria, is intractable and often unresponsive to antihistamines, forcing

excessive disabilities on patients. While further large-scaled clinical investigations will be necessary, omalizumab may be a beneficial therapeutic remedy for patients with intractable chronic inducible urticaria including cholinergic urticaria.

CONFLICT OF INTEREST

The authors declare no conflict of interest.

ORCID

Shinichi Moriwaki  <https://orcid.org/0000-0003-0803-9455>

REFERENCES

- Metz M, Bergmann P, Zuberbier T, Maurer M. Successful treatment of cholinergic urticaria with anti-immunoglobulin E therapy. *Allergy*. 2008;63(2):247-9.
- Kutlu A, Tanoglu A, Ozturk S. Healing effects of omalizumab in a patient with cholinergic urticaria associated severe dyspeptic complaints. *Chin Med J (Engl)*. 2015;128 (11):1559-60.
- Guzelbey O, Ardelean E, Magerl M, Zuberbier T, Maurer M, Metz M. Successful treatment of solar urticaria with anti-immunoglobulin E therapy. *Allergy*. 2008;63(2):1563-5.
- Bito T, Sawada Y, Tokura Y. Pathogenesis of cholinergic urticarial in reaction to swelling. *Allergol Int*. 2012;61(4):539-44.



5. Hirschmann JV, Lawlor F, English JS, Louback JB, Winkelmann RK, Greaves MW. Cholinergic urticaria. A clinical and histologic study. *Arch Dermatol*. 1987; 123(4): 462-7.
6. Vadas P, Sinilaite A, Chaim M. Cholinergic urticaria with anaphylaxis: an underrecognized clinical entity. *J Allergy Clin Immunol Pract*. 2016;4(2):284-91.
7. Fukunaga A, Washio K, Hatakeyama Y, et al. Cholinergic urticaria: epidemiology, physiopathology, new categorization, and management. *Clin Auton Res*. 2018;28(1):103-13.
8. Tokura Y. New etiology of cholinergic urticaria. *Curr Probl Dermatol*. 2016;51:94-100.
9. Metz M, Ohanyan T, Church MK, Maurer M. Retreatment with omalizumab results in rapid remission in chronic spontaneous and inducible urticaria. *JAMA Dermatol*. 2014;150(3):288-90.
10. Metz M, Bergmann P, Zuberbier T, Maurer M. Successful treatment of cholinergic urticaria with anti-immunoglobulin E therapy. *Allergy*. 2008;63(11):247-9.
11. Kaplan AP, Greaves M. Pathogenesis of chronic urticaria. *Clin Exp Allergy*. 2009;39(6):777-87.
12. Hiragun T, Ishii K, Hiragun M, et al. Fungal protein MGL-1304 in sweat is an allergen for atopic dermatitis patients. *J Allergy Clin Immunol*. 2013;132(3):608-15.
13. Adachi J, Aoki T, Yamatodani A. Demonstration of sweat allergy in cholinergic urticaria. *J Dermatol Sci*. 1994;7(2):142-9.
14. Otto HF, Calabria CW. A case of severe refractory chronic urticaria. A novel method for evaluation and treatment. *Allergy Asthma Proc*. 2009; 30(3): 333-7.
15. Altrichter S, Chuamanochan M, Knoth H., et al. Real life treatment of cholinergic urticarial with omalizumab. *J Allergy Clin Immunol*. 2018. pii: S0091-6749(18)31429-5 [Epub ahead of print]. <https://doi.org/10.1016/j.jaci.2018.08.050>

How to cite this article: Yamasaki A, Oda Y, Tanizaki H, et al. Successful treatment of severe cholinergic urticaria with omalizumab: A case report. *J Cutan Immunol Allergy*. 2019;2:31-34. <https://doi.org/10.1002/cia2.12043>