

## A case of atopic dermatitis with hypohidrosis improved after dupilumab treatment

Dear Editor,

Hypohidrosis is the reduction in perspiration in response to thermoregulatory stimulations. This condition leads to heat intolerance and dry skin.<sup>1,2</sup> AD is a known cause of hypohidrosis; however, the pathophysiological mechanism is unclear.<sup>3,4</sup> We presented a case of AD with hypohidrosis, and the symptoms of AD as well as the perspiration were improved after dupilumab treatment.

A 40-year-old man with AD came to our hospital because of ongoing hypohidrosis for 2 years. Although the patient tried topical steroid therapy, neither eczema nor hypohidrosis had never changed. The patient complained of heat intolerance and dot-shaped erythema with prickly pain on the arms in high temperatures. Clinical findings showed scaly erythema and dry skin with scratch marks over the entire body (Figure 1A,B). EASI score was 18.5, and DLQI score was 21. The thermoregulatory sweating test<sup>5</sup> at 43°C for 30 min in footbath revealed sweating points were only on the forehead, bilateral popliteal fossa, and chest (Figure 1C,D). Blood examination revealed high levels of eosinophils, LDH, TARC, and total IgE. We performed skin biopsy from the anhidrotic abdomen and the hidrotic right popliteal fossa. Histopathological findings showed hyperkeratosis and slight acanthosis and superficial perivascular infiltration with some inflammatory cells. The sweat glands and ducts were normal and had no difference between the anhidrotic and hidrotic lesions (Figure 1I,J). Dermcidin is expressed eccrine sweat glands and secreted into sweat.<sup>5</sup> We stained dermcidin to detect eccrine glands and sweat leakage. Dermcidin was positive only within the sweat glands in the hidrotic lesion (Figure 1K). By contrast, dermcidin was positive within sweat glands and surrounding tissue in the anhidrotic lesion (Figure 1L). These findings might indicate that sweat leakage was generated in the anhidrotic lesion, resulting in hypohidrosis.<sup>6,7</sup>

We diagnosed our case as moderate AD complicated with hypohidrosis. In addition to topical steroid therapy, we started dupilumab treatment every two weeks. Following two injections, 1 month after dupilumab initiation, hypohidrosis and heat intolerance as well as eczema were simultaneously improved. Erythema remained only on the scalp and lower extremity (Figure 1E,F). The EASI score improved to 7.9, and DLQI score improved to 8. When we repeated the sweating test, normal perspiration appeared on the entire body (Figure 1G,H).

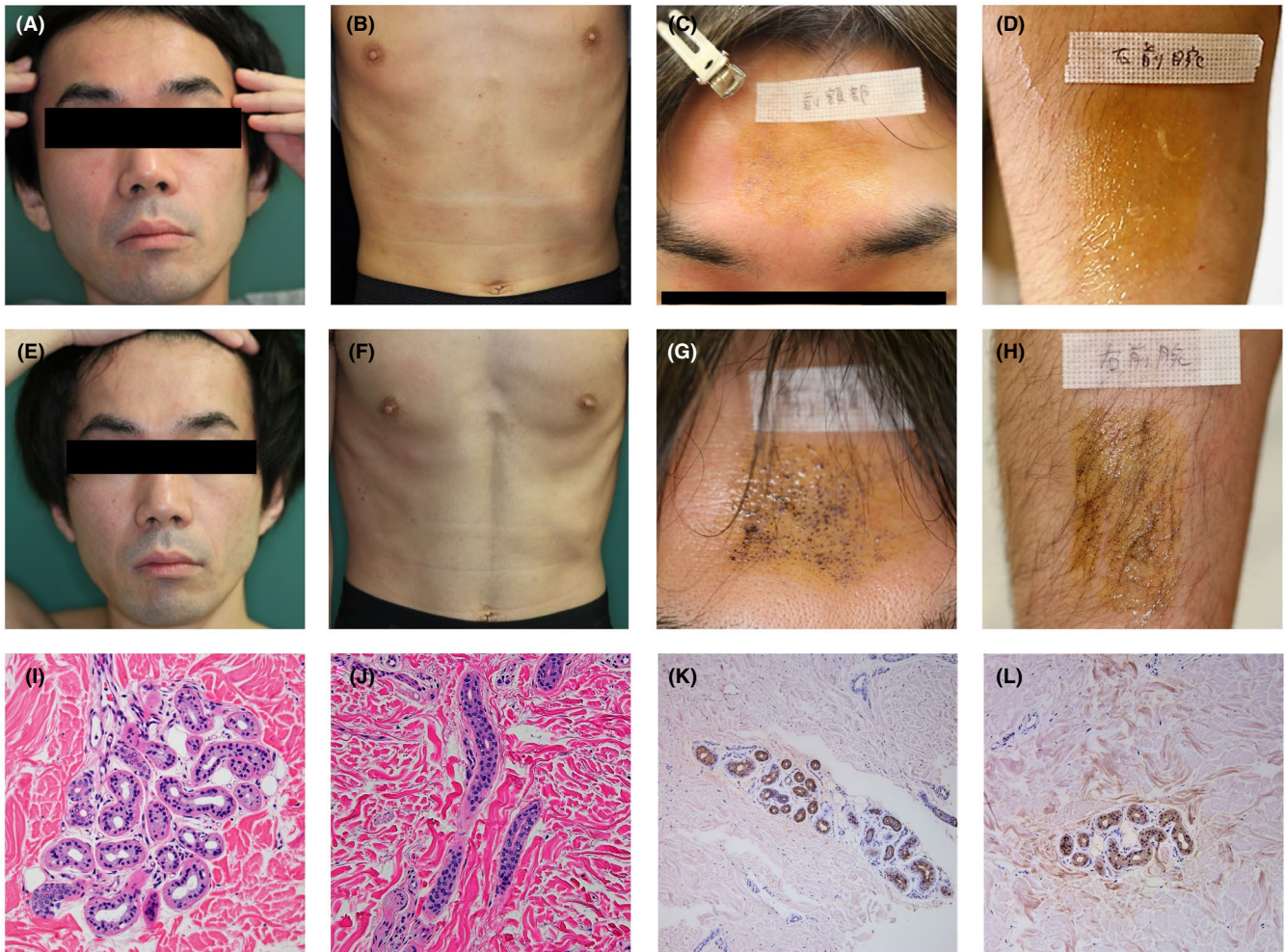
In the differential diagnosis, acquired idiopathic generalized anhidrosis (AIGA) complicated with AD could not be strictly ruled out based on the guideline.<sup>8</sup> Because systemic pulse corticosteroid therapy was reported to be effective for severe AIGA,<sup>9</sup> steroid therapy was one of the treatment options in our case. However, we did not choose steroid therapy firstly because of the risk of an AD rebound phenomenon. AD complicated with hypohidrosis and AIGA should be discriminated more clearly and specifically in the near future guideline.

There were limitations in this report. If we had examined the pathological time-course change before and after dupilumab, we might have observed that sweat leakage decreased after dupilumab. However, we could not ethically recommend second skin biopsy to the improved patient. In conclusion, we demonstrated the possibility of dupilumab for hypohidrosis associated with AD. Barrier junction-related genes, claudins and aquaporin-9, were modulated by dupilumab.<sup>10</sup> Furthermore, dupilumab increased mRNA expression of filaggrin and loricrin in skin lesion, and actual filaggrin staining was increased pathologically.<sup>10</sup> We also speculate that in AD patient with hypohidrosis, dupilumab can ameliorate sweat function and is associated with the improvement of barrier function. Although the mechanism is still unclear, dupilumab might be a treatment option in cases of hypohidrosis complicated with AD.

[Correction added on 21 Oct 2020, after first online publication: Declaration section has been added].

This is an open access article under the terms of the Creative Commons Attribution-NonCommercial-NoDerivs License, which permits use and distribution in any medium, provided the original work is properly cited, the use is non-commercial and no modifications or adaptations are made.

© 2020 The Authors. *Journal of Cutaneous Immunology and Allergy* published by John Wiley & Sons Australia, Ltd on behalf of The Japanese Society for Cutaneous Immunology and Allergy



**FIGURE 1** Clinical findings and histopathological findings. A, B, Clinical manifestations showed scaly erythema with itch on his whole face and the body. C, Sweating points were found only on the forehead as the result of the thermoregulatory sweat test. D, The forearm and body trunk did not perspire at all. E, F, Erythema on the face and the body improved after 2 times injection of dupilumab. G, H, Perspiring function improved on the forehead, the forearm, and the body trunk after 2 times injection of dupilumab. I, J, There were some normal eccrine glands and eccrine ducts in the dermis (hematoxylin and eosin  $\times 400$ ). K, Immunohistochemical stain of dermcidin with the hidrotic lesion was positive in sweat gland. L, However, the immunohistochemical stain of dermcidin with the anhidrotic lesion was positive in sweat glands and surrounding outer tissue (dermcidin  $\times 200$ )

#### ACKNOWLEDGEMENTS

The authors wish to express grateful thanks to Hideki Shimizu from the Department of Dermatology in Sanda City Hospital for referring the patient to our hospital.

#### DECLARATION

Approval of the research protocol: N/A.

Informed Consent: Written informed consent was obtained from the patients.

Registry and the Registration No. of the study/trial: N/A.

Animal Studies: N/A.

#### CONFLICT OF INTEREST

The authors declare no conflict of interest.

#### FUNDING INFORMATION

This work was supported in part by a Grant-in-Aid for Scientific Research (C) (JSPS KAKENHI Grant Number 17K16340) from the Ministry of Education, Culture, Sports, Science, and Technology, Japan (to K.O).

Shinya Imamura MD

Ken Washio MD, PhD

Mayuko Mizuno MD

Yoshiko Oda MD, PhD

Kanako Ogura MD, PhD

Atsushi Fukunaga MD, PhD

Chikako Nishigori MD, PhD

Division of Dermatology, Department of Internal Related, Kobe University Graduate School of Medicine, 7-5-1 Kusunoki-cho, Chuo-ku, Kobe, 650-0017, Japan

#### Correspondence

Atsushi Fukunaga, Department of Internal Related, Division of Dermatology, Kobe University Graduate School of Medicine, 7-5-1 Kusunoki-cho, Chuo-ku, Kobe, 650-0017, Japan.  
Email: atsushi@med.kobe-u.ac.jp

#### ORCID

Shinya Imamura  <https://orcid.org/0000-0001-8670-4997>

Ken Washio  <https://orcid.org/0000-0002-2468-7535>

Mayuko Mizuno  <https://orcid.org/0000-0002-8530-1720>

Yoshiko Oda  <https://orcid.org/0000-0002-5244-0871>

Kanako Ogura  <https://orcid.org/0000-0001-9163-3628>

Atsushi Fukunaga  <https://orcid.org/0000-0003-2026-8154>

Chikako Nishigori  <https://orcid.org/0000-0002-6784-2849>

#### REFERENCES

1. Chia KY, Tey HL. Approach to hypohidrosis. *J Eur Acad Dermatol Venereol.* 2013;27(7):799–804.
2. Fukunaga A, Horikawa T, Sato M, Nishigori C. Acquired idiopathic generalized anhidrosis: possible pathogenic role of mast cells. *Br J Dermatol.* 2009;160(6):1337–40.
3. Shimoda-Komatsu Y, Sato Y, Yamazaki Y, Takahashi R, Shiohara T. A novel method to assess the potential role of sweating abnormalities in the pathogenesis of atopic dermatitis. *Exp Dermatol.* 2018;27(4):386–92.
4. Eishi K, Lee JB, Bae SJ, Takenaka M, Katayama I. Impaired sweating function in adult atopic dermatitis: results of the quantitative sudomotor axon reflex test. *Br J Dermatol.* 2002;147(4):683–8.
5. Fukumoto T, Tsuchiyama S, Fukunaga A, Nishigori C. Hypohidrosis and metal allergy: trigger factors for unilateral lichen planus. *J Dermatol.* 2017;44(8):963–6.
6. Murota H, Yamaga K, Ono E, Katayama I. Sweat in the pathogenesis of atopic dermatitis. *Allergol Int.* 2018;67(4):455–9.
7. Rieg S, Garbe C, Sauer B, Kalbacher H, Schittek B. Dermcidin is constitutively produced by eccrine sweat glands and is not induced in epidermal cells under inflammatory skin conditions. *Br J Dermatol.* 2004;151(3):534–9.
8. Munetsugu T, Fujimoto T, Oshima Y, Sano K, Murota H, Satoh T, et al. Revised guideline for the diagnosis and treatment of acquired idiopathic generalized anhidrosis in Japan. *J Dermatol.* 2017;44(4):394–400.
9. Fukunaga A, Hatakeyama M, Tsujimoto M, Oda Y, Washio K, Nishigori C. Steroid treatment can improve the impaired quality of life of patients with acquired idiopathic generalized anhidrosis. *Br J Dermatol.* 2015;172(2):537–8.
10. Guttman-Yassky E, Bissonnette R, Ungar B, Suarez-Farinas M, Ardeleanu M, Esaki H, et al. Dupilumab progressively improves systemic and cutaneous abnormalities in patients with atopic dermatitis. *J Allergy Clin Immunol.* 2019;143(1):155–72.