


CASE STUDY

Effectiveness of tacrolimus ointment on facial lesions refractory to topical corticosteroid in patients with atopic dermatitis receiving dupilumab

Hideaki Uchida MD | Masahiro Kamata MD PhD  | Shota Egawa MD |
Mayumi Nagata MD | Saki Fukaya MD | Kotaro Hayashi MD PhD |
Atsuko Fukuyasu MD | Takamitsu Tanaka MD PhD | Takeko Ishikawa MD PhD |
Takamitsu Ohnishi MD PhD | Yayoi Tada MD PhD

Department of Dermatology, Teikyo University School of Medicine, Tokyo, Japan

Correspondence

Masahiro Kamata, Department of Dermatology, Teikyo University School of Medicine, 2-11-1 Kaga, Itabashi-ku, Tokyo 173-8605, Japan.
E-mail: mkamata-tky@umin.ac.jp

Abstract

Dupilumab demonstrated high efficacy and tolerable safety profiles in moderate-to-severe atopic dermatitis (AD) patients in clinical trials; however, certain patients suffer from facial redness, while obtaining good responses on the trunk and limbs to dupilumab in the real-world setting. In our study, we investigated the effectiveness of tacrolimus ointment on facial lesions refractory to topical corticosteroid in patients with AD receiving dupilumab. This study included Japanese adult patients with moderate-to-severe AD who developed facial lesions during dupilumab treatment and whose facial lesions became refractory to topical corticosteroid treatment. Nine patients (one female, eight males) were included in this study. One patient newly developed facial erythema after initiating dupilumab. Facial lesions were refractory to dupilumab treatment in the other patients. Five of the nine patients showed improvement in EASI scores of head and neck by switching the facial treatment from topical corticosteroid to tacrolimus ointment. The patient who developed newly facial erythema showed improvement after applying tacrolimus ointment. Although we explored the predictors of effectiveness of tacrolimus ointment in patients with facial lesions during dupilumab treatment, no significant differences were observed in age, duration of dupilumab prior treatment, or prior head and neck EASI between patients who showed improvement after changing to tacrolimus and those who did not. Tacrolimus ointment is worth trying if facial lesions are refractory to topical corticosteroid.

KEYWORDS

atopic dermatitis, calcineurin, dupilumab, interleukin-4 receptor, tacrolimus

This is an open access article under the terms of the Creative Commons Attribution-NonCommercial License, which permits use, distribution and reproduction in any medium, provided the original work is properly cited and is not used for commercial purposes.

© 2021 The Authors. *Journal of Cutaneous Immunology and Allergy* published by John Wiley & Sons Australia, Ltd on behalf of The Japanese Society for Cutaneous Immunology and Allergy

1 | INTRODUCTION

Atopic dermatitis (AD) is a chronic inflammatory skin disease with pruritus, characterized by recurrent eczema with exacerbations and remissions, and impairs patients' quality of life. Dupilumab, an anti-interleukin (IL)-4 receptor α antibody, demonstrated high efficacy and tolerable safety profiles in patients with moderate-to-severe AD in clinical trials.^{1,2} In the real-world setting, dupilumab also showed high effectiveness;³⁻⁵ however, certain patients showed poor improvement on the head and neck while obtaining good responses on the trunk and limbs to dupilumab.³ Zhu et al.⁶ reported that among 73 patients with a median duration of dupilumab therapy of 181 days, 14 patients (19.2%) developed new regional dermatoses of the face. These facial lesions that develop during dupilumab treatment are often refractory to topical corticosteroid, and bother patients. We experienced nine adult patients with facial lesions that were refractory to topical corticosteroid during dupilumab treatment who changed their facial treatment from topical corticosteroid to tacrolimus ointment and herein discuss the effectiveness of tacrolimus for these facial lesions.

2 | METHODS

This study included Japanese adult patients with moderate-to-severe AD who developed facial lesions during dupilumab treatment and whose facial lesions became refractory to topical corticosteroid treatment. Under the insurance system in Japan, dupilumab is indicated only for AD patients over 15 years old with a total eczema area and severity index (EASI) score of greater than 16 or a head and neck EASI score of greater than 2.4, an investigator's global assessment score of >3 , and affected body surface area of greater than 10%, who have been refractory to topical corticosteroid and/or tacrolimus for more than six months or cannot use them due to adverse effects. All patients received a 600 mg loading dose of dupilumab once; then, starting two weeks later, 300 mg of dupilumab was administered subcutaneously every two weeks, in addition to treatment with topical corticosteroid and/or tacrolimus for lesions other than lesions on the face. Facial lesions were initially treated with topical corticosteroid. If improvement in the facial lesions was not observed under the treatment of topical corticosteroid at more than two consecutive visits, the patients changed the facial treatment from topical corticosteroid to tacrolimus ointment. The severity of AD was evaluated by dermatologists using EASI. All data were collected retrospectively from their charts. Statistical differences in demographic and clinical backgrounds between patients who showed improvement after changing to tacrolimus and those who did not were evaluated using Student's *t* test after confirming the normal distribution of the groups by the Shapiro-Wilk test. This study was approved by the ethics committee of Teikyo University and was carried out under the principles of the Declaration of Helsinki.

3 | RESULTS

Patients' demographics, clinical characteristics, and change in EASI scores of the head and neck over time are shown in Table 1. Two representative cases are described below. Among the nine patients who met the study criteria, eight were male and one was female. The mean age of the nine patients was 45.7 (range, 33-59) years. They applied hydrocortisone butyrate, betamethasone valerate, dexamethasone propionate, or prednisolone valerate acetate ointment on their face for the facial lesions. One patient newly developed facial erythema after initiating dupilumab (Case 2). Facial lesions were refractory to dupilumab treatment in the other patients. After the topical corticosteroid treatment became ineffective, the medication was switched to tacrolimus ointment. Five (55.6%) of the nine patients showed improvement in EASI score of the head and neck by switching the facial treatment from topical corticosteroid to tacrolimus ointment. The patient who developed newly facial erythema showed improvement after applying tacrolimus ointment. Although we explored the predictors of effectiveness of tacrolimus ointment in patients with facial lesions during dupilumab treatment, no significant differences were observed in age, duration of dupilumab prior treatment, or prior head and neck EASI between patients who showed improvement after changing to tacrolimus and those who did not (data are not shown).

3.1 | Case 1

A 49-year-old man with AD since childhood had been treated with clobetasol propionate ointment and diflorasone diacetate ointment for lesions on his trunk and extremities, and with betamethasone valerate ointment for lesions on his face until initiating dupilumab. At the time of beginning dupilumab treatment, his total EASI score was 39.1, and EASI score of the head and neck was 5.4. One month later, his total EASI score and EASI score of the head and neck decreased to 27.45 and 4, respectively. On four months after initiation of dupilumab, erythema and papules were still persistent on his face despite treatment with topical corticosteroid, with a head and neck EASI score of 2.2. For his refractory residual facial lesions, the topical corticosteroid was switched to tacrolimus ointment. After eight months, his erythematous facial lesions ameliorated, with a head and neck EASI score of 1.6 (Figure 1A).

3.2 | Case 2

A 59-year-old man had suffered from AD and bronchial asthma since he was three years old. He has applied betamethasone butyrate propionate ointment on his trunk and extremities, and hydrocortisone butyrate ointment on his face for the treatment of AD. His total EASI score was 26.9 and the EASI score of the head and neck was 3 at the time of beginning dupilumab. Six-month treatment with dupilumab in addition to corticosteroid ointment

TABLE 1 Demographics and clinical characteristics of patients who applied tacrolimus ointment for the treatment of facial lesions that had been refractory to topical corticosteroid during dupilumab therapy

Case	Age (year)	Sex	Duration of dupilumab therapy before initiating application of tacrolimus ointment (months)	Treatment prior to applying tacrolimus ointment	Type of facial redness	EASI (H&N) before applying tacrolimus ointment	Duration of applying tacrolimus ointment (months)	EASI (H&N) after application of tacrolimus	Outcome: Change in EASI (H&N)
1	49	M	4	Betamethasone valerate	Refractory	2.2	8	1.6	-0.6
2	59	M	4	Hydrocortisone butyrate	Newly developed	5	8	1.5	-3.5
3	33	M	6	Dexamethasone propionate hydrocortisone butyrate	Refractory	0.3	6	0.1	-0.2
4	56	M	7	Hydrocortisone butyrate	Refractory	1.5	6	3.5	+2
5	49	M	7	Hydrocortisone butyrate	Refractory	0.2	5	0	-0.2
6	40	M	5	Hydrocortisone butyrate	Refractory	1.2	6	1.6	+0.4
7	35	M	3	Betamethasone valerate	Refractory	0.2	9	0.9	+0.7
8	35	M	3	Prednisolone valerate acetate	Refractory	2.4	3	0.4	-2
9	55	F	2	Hydrocortisone butyrate	Refractory	0.8	10	1.2	+0.4

Abbreviations: EASI, eczema area and severity index; H&N, head and neck.

decreased his total EASI score to 21.8, whereas it did not bring any improvement in his facial lesions. Rather, new erythematous lesions developed on his face, with a head and neck EASI score of 5. Since hydrocortisone butyrate ointment did not bring any improvement in his facial lesions under the treatment of dupilumab, he started to apply tacrolimus ointment instead. Application of tacrolimus ointment on his face for 8 months resulted in certain improvement of facial lesions, with a head and neck EASI score of 1.5 (Figure 1B).

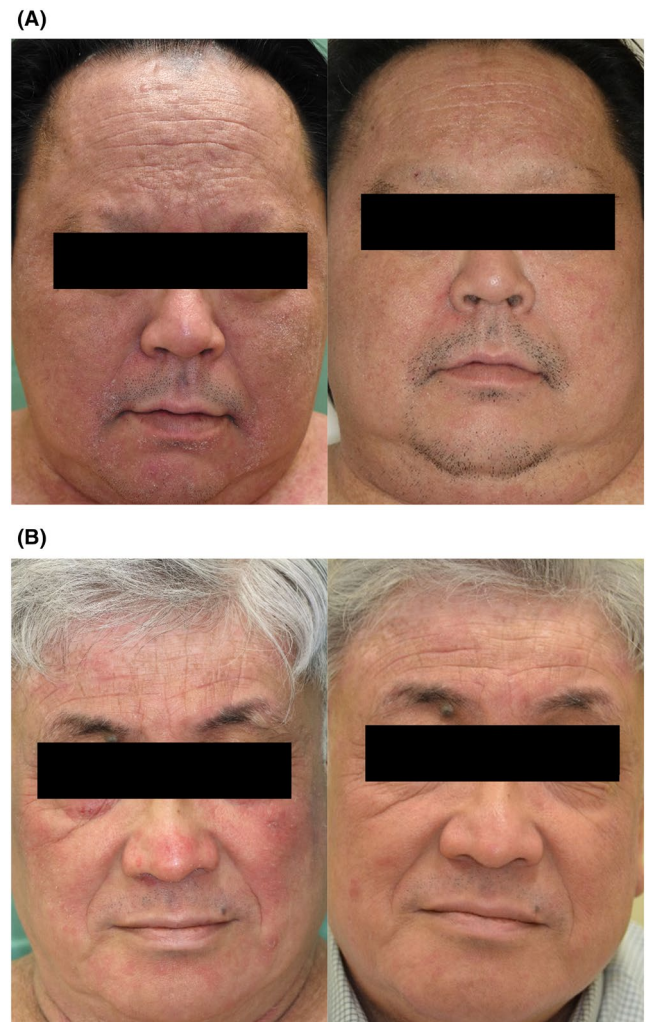


FIGURE 1 Representative cases of facial lesions in patients with atopic dermatitis (AD) who were being treated with dupilumab before and after tacrolimus therapy. A, Case 1. Eczematous lesions on the face that were refractory to topical corticosteroid improved after eight months' application of tacrolimus ointment. B, Case 2. Erythema on the face that was refractory to topical corticosteroid improved after eight months' application of tacrolimus ointment. Left panels show the skin manifestation of facial lesions before starting application of tacrolimus ointment. Right panels show the skin manifestation after application of tacrolimus ointment for eight months

4 | DISCUSSION

The pathogenesis of facial redness that develops after some AD patients initiate dupilumab treatment remains to be elucidated. Waldman et al.⁷ reported that prevailing theories for the pathogenesis of dupilumab facial redness were hypersensitivity reaction, site-specific failure, seborrheic dermatitis, and allergic contact dermatitis. There is some evidence supporting each theory, while there is other refuting evidence. Heibel et al.⁸ reported a case with rosacea associated with dupilumab therapy. De Wijs et al.⁹ reported heterogeneous clinical and histopathological characteristics of paradoxical head and neck erythema in atopic dermatitis patients treated with dupilumab and advocated the possibility of a drug-induced skin reaction. These previous literatures indicate that facial redness after dupilumab treatment is heterogeneous, and that further accumulation of cases is needed to elucidate its pathogenesis.

Our study showed that in five of nine patients, tacrolimus ointment was effective for facial lesions that had been refractory to topical corticosteroid during dupilumab treatment. Previous literatures revealed differences in the mechanism of the effectiveness of corticosteroid and tacrolimus for AD, although there are certain common mechanisms of action between them. Noguchi et al. developed NC/Nga mice with AD-like dermatitis by repeated topical application of *Dermatophagoides farinae* body ointment and reported that transepidermal water loss was significantly lower in tacrolimus-treated AD mice, but not in clobetasol propionate-treated AD mice, than in vaseline-treated AD mice.¹⁰ In *in vitro* studies, Kato et al.¹¹ stimulated human peripheral blood-derived mast cells with anti-IgE antibody in the presence of dexamethasone or tacrolimus. Induction of CCL2, CCL7, CXCL3, and CXCL8 by anti-IgE was significantly inhibited by dexamethasone but was enhanced by tacrolimus. In contrast, induction of CCL1, CCL3, CCL4, and CCL18 was significantly inhibited by tacrolimus but, with the exception of CCL1, was enhanced by dexamethasone, indicating that the corticosteroid and tacrolimus inhibited the expression of distinct subsets of chemokines in mast cells. Inagaki et al. reported that in a mouse allergic dermatitis model involving frequent scratching behavior by repeated painting with 2,4-dinitrofluorobenzene acetone solution onto the mouse skin, tacrolimus significantly inhibited the scratching behavior that was associated with the inhibition of nerve fiber extension into the epidermis, whereas dexamethasone failed to have any effect.¹² These previous literatures demonstrated the difference in the mechanism of action between corticosteroid and tacrolimus. In AD, heterogeneity is identified by the race,¹³ the biomarkers,¹⁴ and severity of itch and skin lesions.¹⁵ This concept of heterogeneity in the pathogenesis of AD is also supported by the fact that there are still a certain number of patients with significant failure even in any systemic therapies.¹⁶ Considering this heterogeneity and the different mechanisms of actions between corticosteroid and tacrolimus, it is reasonable that there are some patients with facial lesions during dupilumab treatment, which are refractory to topical corticosteroid but responsive to topical tacrolimus.

Regarding the four cases without improvement after switching to tacrolimus ointment, topical corticosteroid might have been more effective than tacrolimus ointment due to their different mechanism of action; however, tacrolimus ointment is recommended in terms of adverse effects of long-term use of topical corticosteroids such as telangiectasia and thinning of the skin. As another possibility, AD is a chronic inflammatory disease with flares and remissions, which may affect the results. In addition, adherence is another problem considering topical treatment. Generally, as treatment become longer, the adherence of topical treatment decreases.¹⁷ In our study, we did not investigate the adherence, which is one of the limitations. Further investigation is needed to elucidate the reason of the four cases without improvement after switching to tacrolimus ointment.

We could not find any statistical differences in demographic and clinical backgrounds between patients who showed improvement after changing to tacrolimus and those who did not. This may be due to the small sample of our study, which is one of limitations. Further accumulation of cases is needed to clarify this issue.

In conclusion, we experienced patients with facial lesions that were refractory to topical corticosteroid during dupilumab treatment who were successfully treated with tacrolimus ointment. Our study suggests that tacrolimus may be one of the good treatment options for patients who develop refractory facial lesions while receiving dupilumab. Tacrolimus ointment is worth trying even if the facial lesions had been refractory to topical corticosteroid.

DECLARATION SECTION

Approval of the research protocol: This study was approved by the ethics committee of Teikyo University and was carried out under the principles of the Declaration of Helsinki.

Informed Consent: Informed consent was obtained in the form of opt-out on the website.

Registry and the Registration No. of the study/trial: N/A.

Animal Studies: N/A.

CONFLICT OF INTEREST

M.K. received lecture fees from Sanofi and Maruho Co., Ltd. Y.T. received research grants, which are not related to this work from Sanofi and Maruho Co., Ltd.

H.U. and M.K. designed the study and wrote the manuscript. All authors contributed to data collection. H.U. performed the statistical analysis and interpretation of the results. All authors read and approved the final manuscript.

ORCID

Masahiro Kamata  <https://orcid.org/0000-0003-0976-4982>

REFERENCES

1. Thaçi D, Simpson EL, Beck LA, Bieber T, Blauvelt A, Papp K, et al. Efficacy and safety of dupilumab in adults with moderate-to-severe atopic dermatitis inadequately controlled by topical treatments: a randomised, placebo-controlled, dose-ranging phase 2b trial. *Lancet*. 2016;387(10013):40–52.

2. Blauvelt A, de Bruin-Weller M, Gooderham M, Cather JC, Weisman J, Pariser D, et al. Long-term management of moderate-to-severe atopic dermatitis with dupilumab and concomitant topical corticosteroids (LIBERTY AD CHRONOS): a 1-year, randomised, double-blinded, placebo-controlled, phase 3 trial. *Lancet*. 2017;389(10086):2287–303.
3. Uchida H, Kamata M, Mizukawa I, Watanabe A, Agematsu A, Nagata M, et al. Real-world effectiveness and safety of dupilumab for the treatment of atopic dermatitis in Japanese patients: a single-centre retrospective study. *Br J Dermatol*. 2019;181(5):1083–5.
4. Uchida H, Kamata M, Kato A, Mizukawa I, Watanabe A, Agematsu A, et al. One-year real-world clinical effectiveness, safety, and laboratory safety of dupilumab in Japanese adult patients with atopic dermatitis: A single-center retrospective study. *J Am Acad Dermatol*. 2021;84(2):547–50.
5. Matsutani M, Imai Y, Inoue Y, Hosotani Y, Kusakabe M, Natsuaki M, et al. Real-world use of dupilumab for 53 patients with atopic dermatitis in Japan. *J Cutaneous Immunol Allergy*. 2020;3(2):35–6.
6. Zhu GA, Chen JK, Chiou A, Ko J, Honari G. Assessment of the development of new regional dermatoses in patients treated for atopic dermatitis with dupilumab. *JAMA Dermatol*. 2019;155(7):850–2.
7. Waldman RA, DeWane ME, Sloan B, Grant-Kels JM. Characterizing dupilumab facial redness: a multi-institution retrospective medical record review. *J Am Acad Dermatol*. 2020;82(1):230–2.
8. Heibel HD, Hendricks AJ, Foshee JP, Shi VY. Rosacea associated with dupilumab therapy. *J Dermatolog Treat*. 32(1):114–6.
9. de Wijs LEM, Nguyen NT, Kunkeler ACM, Nijsten T, Damman J, Hijnen DJ. Clinical and histopathological characterization of paradoxical head and neck erythema in patients with atopic dermatitis treated with dupilumab: a case series. *Br J Dermatol*. 2020;183(4):745–9.
10. Noguchi A, Tominaga M, Takahashi N, Matsuda H, Kamata Y, Umehara Y, et al. Differences in therapeutic effects of topically applied corticosteroid and tacrolimus on atopic dermatitis-like symptoms in NC/Nga mice. *J Dermatol Sci*. 2017;86(1):54–62.
11. Kato A, Chustz RT, Ogasawara T, Kulka M, Saito H, Schleimer RP, et al. Dexamethasone and FK506 inhibit expression of distinct subsets of chemokines in human mast cells. *J Immunol*. 2009;182(11):7233–43.
12. Inagaki N, Shiraishi N, Igeta K, Itoh T, Chikumoto T, Nagao M, et al. Inhibition of scratching behavior associated with allergic dermatitis in mice by tacrolimus, but not by dexamethasone. *Eur J Pharmacol*. 2006;546(1–3):189–96.
13. Noda S, Suárez-Fariñas M, Ungar B, Kim SJ, de Guzman Strong C, Xu H, et al. The Asian atopic dermatitis phenotype combines features of atopic dermatitis and psoriasis with increased TH17 polarization. *J Allergy Clin Immunol*. 2015;136(5):1254–64.
14. Sims JT, Chang CY, Higgs RE, Engle SM, Liu Y, Sissons SE, et al. Insights into adult atopic dermatitis heterogeneity derived from circulating biomarker profiling in patients with moderate-to-severe disease. *Exp Dermatol*. 2021;30(11):1650–1661.
15. Chovatiya R, Lei D, Ahmed A, Chavda R, Gabriel S, Silverberg JI. Clinical phenotyping of atopic dermatitis using combined itch and lesional severity: A prospective observational study. *Ann Allergy Asthma Immunol*. 2021;127(1):83–90.e2.
16. Silverberg JI, Thyssen JP, Fahrbach K, Mickle K, Cappelleri JC, Romero W, et al. Comparative efficacy and safety of systemic therapies used in moderate-to-severe atopic dermatitis: a systematic literature review and network meta-analysis. *J Eur Acad Dermatol Venereol*. 2021;35(9):1797–1810.
17. Zaghoul SS, Goodfield MJ. Objective assessment of compliance with psoriasis treatment. *Arch Dermatol*. 2004;140(4):408–14.

How to cite this article: Uchida H, Kamata M, Egawa S, Nagata M, Fukaya S, Hayashi K, et al. Effectiveness of tacrolimus ointment on facial lesions refractory to topical corticosteroid in patients with atopic dermatitis receiving dupilumab. *J Cutan Immunol Allergy*. 2022;5:17–21. <https://doi.org/10.1002/cia2.12201>