

CORRESPONDENCE

Refractory myositis in a patient of Sjögren's syndrome having only anti-SS-A (60 kDa) antibody

Dear Editor,

A 46-year-old Japanese female patient had noticed asymptomatic eruptions on her legs several years ago and visited our hospital in 2015. Physical examination showed purpuras with mild induration and scattered pigmentation (Figure 1A, B). Manual muscle test revealed muscle weakness with a score of 4 on her upper and lower extremities. Laboratory investigation showed an increase in serum creatine kinase (CK; 450 U/L), aldolase (9.0 IU/L), immunoglobulin G (2315 mg/dL), and the presence of cryoglobulin, antinuclear antibody ($\times 640$; speckle pattern), and autoantibodies against SS-A/Ro (>1200 U/mL). Other autoantibodies were not detected by enzyme-linked immunosorbent assay. A biopsy specimen from

a purpura on her leg showed leukocytoclastic vasculitis in the superficial dermis (Figure 1C, D). Direct immunofluorescence examination demonstrated the deposition of C3 on the vessels in the superficial dermis. (Figure 1E). A deltoid muscle biopsy showed mild myositis (Figure 1F). A biopsy specimen from minor salivary gland on the lip showed more than 50 mononuclear cells infiltration (Figure 1G). Immunoprecipitation assays for RNA (left) using nonradiolabeled K562 cell extracts and for protein (right) using 35S-methionine-labeled K562 cell extracts in our case revealed anti-SS-A (60 kDa) antibody (Figure 1H). We diagnosed her with primary Sjögren's syndrome with myositis and hypergammaglobulinemic purpura. Regarding differential diagnosis, myopathy associated with

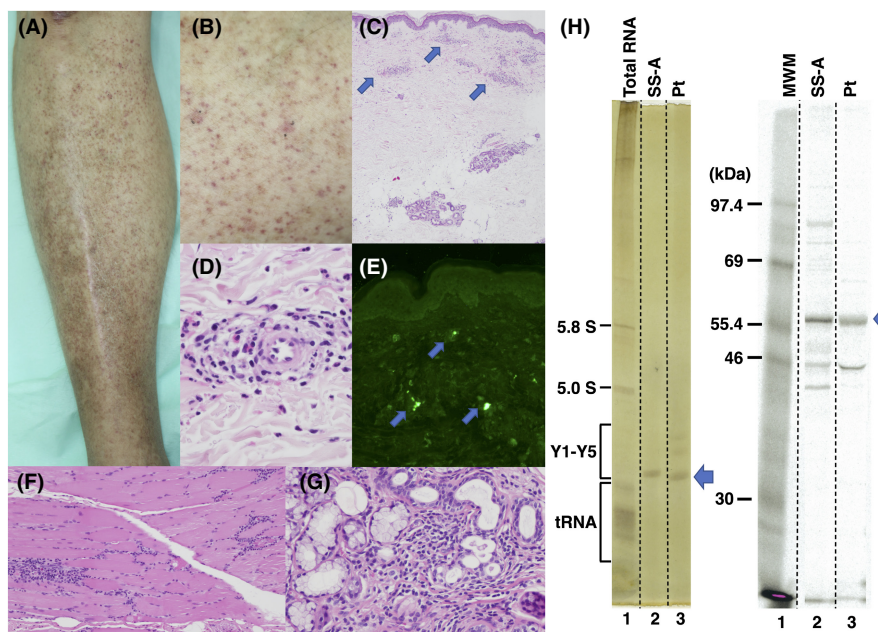


FIGURE 1 (A and B) Clinical presentation at first visit. Physical examination showed a lot of purpura with mild induration and scattered pigmentation. (C and D) Histopathological findings of the cutaneous biopsy specimen from a purpura on her leg showed leukocytoclastic vasculitis in the superficial dermis [hematoxylin-eosin (H&E) staining; original magnification, $\times 40$ (C) and $\times 400$ (D)]. (E) Direct immunofluorescence examination demonstrated the deposition of C3 on the vessels in the superficial dermis. (F) A deltoid muscle biopsy showed mild myositis (H&E staining; original magnification, $\times 100$). (G) A biopsy specimen for minor salivary gland on the lip showed more than 50 mononuclear cells infiltration around the gland (H&E staining; original magnification, $\times 200$). (H) Immunoprecipitation assays for RNA (left) using nonradiolabeled K562 cell extracts and for protein (right) using 35S-methionine-labeled K562 cell extracts in our case revealed anti-SS-A (60 kDa) antibody

This is an open access article under the terms of the [Creative Commons Attribution-NonCommercial-NoDerivs](https://creativecommons.org/licenses/by-nc-nd/4.0/) License, which permits use and distribution in any medium, provided the original work is properly cited, the use is non-commercial and no modifications or adaptations are made.

© 2021 The Authors. *Journal of Cutaneous Immunology and Allergy* published by John Wiley & Sons Australia, Ltd on behalf of The Japanese Society for Cutaneous Immunology and Allergy.

cryoglobulinemic vasculitis was included. While it is usually accompanied by arthralgia, peripheral neuropathy, and haematuria,¹ she had no symptoms of them. To improve myositis, oral prednisolone of 20 mg/day was not enough and 45 mg (1 mg/kg) was needed. We reduced the dosage after 4 weeks; then, myositis recurred in 2016. We additionally administered azathioprine (100 mg/day), intravenous immunoglobulin (IVIG; 400 mg/kg/day, 5 days, 3 times) in 2017, tacrolimus (2-3 mg/day) in 2018, or methotrexate (4-6 mg/week) in 2019, which could not improve myositis completely.

Myositis in Sjögren's syndrome usually responds well to small or moderate doses of prednisolone without a recurrence.² However, our case needed high doses of prednisolone and various additional treatments for recurrences. Autoantibodies are divided into myositis-specific antibody (MSA) such as antimelanoma differentiation-associated gene 5 (MDA5) and myositis-associated antibody (MAA) such as SS-B/La and SS-A/Ro. Whereas the concurrent presence of more than one MSA in one patient is rare, MAAs are frequently observed with MSAs. Two different targets of proteins, Ro52 and Ro60, were identified regarding SS-A. In general adult population having anti-SS-A antibodies, the profile of Ro52-Ro60+ was found in 24%.³ However, the profile of Ro52-Ro60+ seems to be extremely rare in Japanese patients with polymyositis/dermatomyositis (PM/DM),⁴ and Sjögren's syndrome with myositis having only anti-SS-A antibody is also rare.² Anti-SS-A antibody could induce PM/DM through activating interferon- α production.⁵ Recent studies reported that anti-SS-A/Ro52 antibody was a risk factor for relapse in PM/DM⁶ and associated with poor prognosis in anti-MDA5-antibody-positive PM/DM.⁷ Anti-SS-A/Ro60 antibody can function as a Y RNA-free protein,⁸ but the details are still unclear. These studies mentioned not about anti-SS-A/Ro60, but only about anti-SS-A/Ro52. We suggest a possibility that not only anti-SS-A/Ro52 but also anti-SS-A/Ro60 may contribute to the resistance in the same way.

KEYWORDS

azathioprine, intravenous immunoglobulin, methotrexate, myositis, Sjögren's syndrome, tacrolimus

ACKNOWLEDGMENT

None.

CONFLICT OF INTEREST

The authors declare no conflict of interest.

DECLARATION SECTION

Approval of the research protocol: N/A.

Informed consent: Informed consent was obtained.

Registry and the Registration No. of the study/trial: N/A.

Animal Studies: N/A.

Hiraku Kokubu MD¹ 

Yasuhito Hamaguchi MD, PhD² 

Takeshi Kato MD, PhD¹

Toshihiro Tanaka MD, PhD¹

Noriki Fujimoto MD, PhD¹ 

¹Department of Dermatology, Shiga University of Medical Science, Otsu, Japan

²Department of Dermatology, Faculty of Medicine, Institute of Medical, Pharmaceutical and Health Sciences, Kanazawa University, Kanazawa, Japan

Correspondence

Hiraku Kokubu MD, Department of Dermatology, Shiga University of Medical Science, Setatsukinowa, Otsu, Shiga 520-2192, Japan.

Email: kokubu@belle.shiga-med.ac.jp

ORCID

Hiraku Kokubu  <https://orcid.org/0000-0003-4023-367X>

Yasuhito Hamaguchi  <https://orcid.org/0000-0001-5305-7770>

Noriki Fujimoto  <https://orcid.org/0000-0003-4051-0649>

REFERENCES

- Rodriguez-Perez N, Rodriguez-Navedo Y, Font YM, Vila LM. Inflammatory myopathy as the initial presentation of cryoglobulinemic vasculitis. *BMJ Case Rep.* 2013;2013:bcr2013010117.
- Aoki A, Ono S, Ueda A, Hagiwara E, Tsuji T, Misumi M, et al. Myositis in primary Sjogren's syndrome: clinical and pathological report. *Mod Rheumatol.* 2003;13(1):57-61.
- Robbins A, Hentzien M, Toquet S, Didier K, Servettaz A, Pham B-N, et al. Diagnostic Utility of Separate Anti-Ro60 and Anti-Ro52/TRIM21 Antibody Detection in Autoimmune Diseases. *Front Immunol.* 2019;10:444.
- Kubo M, Ihn H, Asano Y, Yamane K, Yazawa N, Tamaki K. Prevalence of 52-kd and 60-kd Ro/SS-A autoantibodies in Japanese patients with polymyositis/dermatomyositis. *J Am Acad Dermatol.* 2002;47(1):148-51.
- Eloranta ML, Barbasso Helmers S, Ulfgren AK, Ronnblom L, Alm GV, Lundberg IE. A possible mechanism for endogenous activation of the type I interferon system in myositis patients with anti-Jo-1 or anti-Ro 52/anti-Ro 60 autoantibodies. *Arthritis Rheum.* 2007;56(9):3112-24.
- Tatebe N, Sada K-E, Asano Y, Zeggar S, Hiramatsu S, Miyawaki Y, et al. Anti-SS-A/Ro antibody positivity as a risk factor for relapse in patients with polymyositis/dermatomyositis. *Mod Rheumatol.* 2018;28(1):141-6.
- Temmoku J, Sato S, Fujita Y, Asano T, Suzuki E, Kanno T, et al. Clinical significance of myositis-specific autoantibody profiles in Japanese patients with polymyositis/dermatomyositis. *Medicine.* 2019;98(20):e15578.
- Bocitto M, Wolin SL. Ro60 and Y RNAs: structure, functions, and roles in autoimmunity. *Crit Rev Biochem Mol Biol.* 2019;54(2):133-52.

How to cite this article: Kokubu H, Hamaguchi Y, Kato T, Tanaka T, Fujimoto N. Refractory myositis in a patient of Sjögren's syndrome having only anti-SS-A (60 kDa) antibody. *J Cutan Immunol Allergy.* 2022;5:102-103. <https://doi.org/10.1002/cia.21228>