

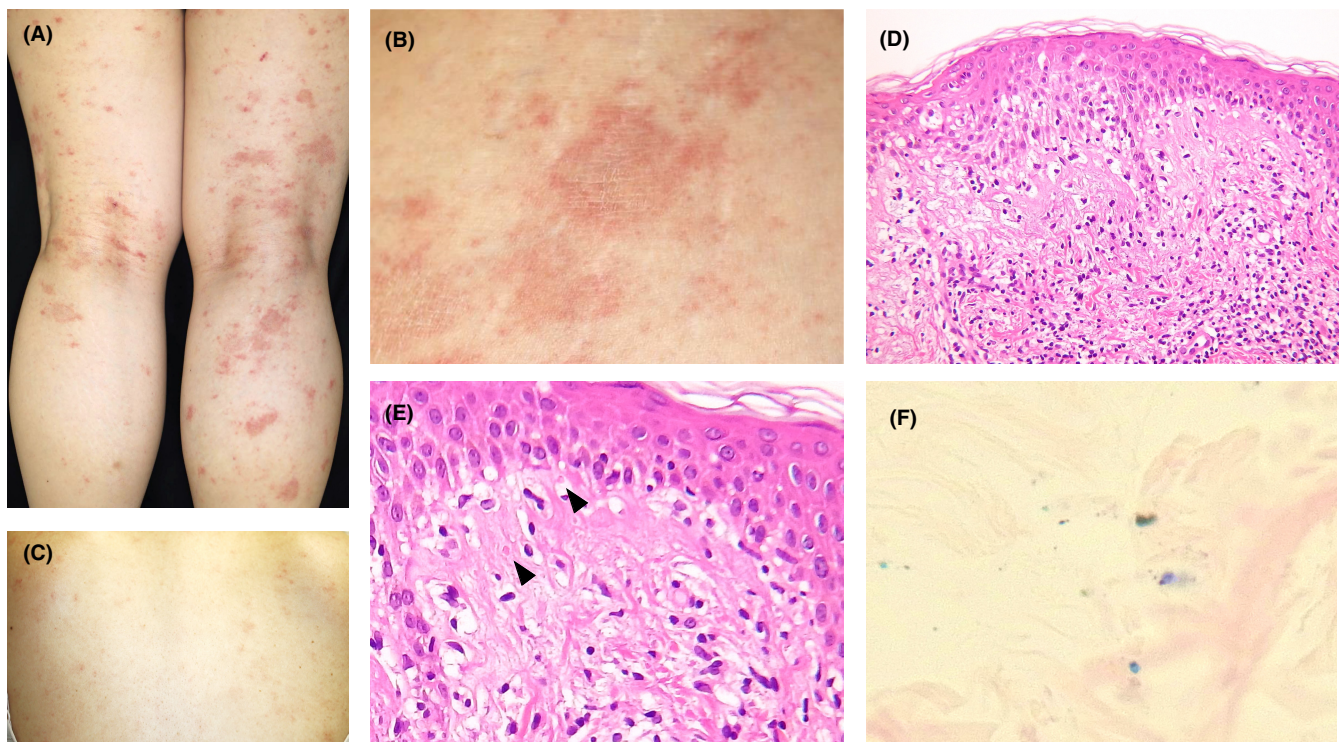
## CORRESPONDENCE

## Development of Schamberg's disease after SARS-CoV-2 vaccination

Pigmented purpuric dermatoses, also known as purpura pigmentosa chronica, are characterized by purpura, petechiae, and pigmentation with histopathological features of lymphocytic infiltration, erythrocytes extravasation, and hemosiderin deposition in the upper dermis.<sup>1</sup> This group of disorders includes Schamberg's disease, Majocchi's disease, Gougerot-Blum's disease, and lichen aureus. Schamberg disease, a representative of this group, commonly affects the tibial regions, calves, thighs, buttocks, trunk, or upper extremities. T-cell-mediated capillaritis has been proposed to induce the disorders,<sup>1</sup> and various causative factors are involved. We report

a patient with Schamberg's disease occurring after SARS-CoV-2 vaccination.

A 43-year-old woman was referred to us because of an eruption on the lower limbs. She received the first dose of SARS-CoV-2 vaccine (Pfizer-BioNTech) and had a mild fever-up and general fatigue on the next day. Three days after vaccination, the patient developed a purpuric eruption on the lower extremities, extending to the buttocks. There was no previous episode of purpuric dermatoses. On examination, she had purpuric, erythematous macules on both flexor and extensor surfaces of bilateral lower extremities,



**FIGURE 1** Clinical photographs and histopathological findings. (A) Purpuric pigmented lesions on the lower extremities. (B) Annularly configured lesions on the calf. (C) Mild eczematoid purpuric lesions on the back. (D) Histopathology, showing infiltration of lymphocytes with an interface change. (E) Erythrocyte extravasation in the upper dermis. (F) Iron staining

This is an open access article under the terms of the [Creative Commons Attribution-NonCommercial](https://creativecommons.org/licenses/by-nc/4.0/) License, which permits use, distribution and reproduction in any medium, provided the original work is properly cited and is not used for commercial purposes.

© 2022 The Authors. *Journal of Cutaneous Immunology and Allergy* published by John Wiley & Sons Australia, Ltd on behalf of The Japanese Society for Cutaneous Immunology and Allergy

extending to the posterior surface of the thighs (Figure 1A). Some of the individual lesions had annular configuration (Figure 1B). Mild lesions were also observed on the back (Figure 1C). Laboratory examination showed no abnormalities in blood cell counts, chemistry, or coagulation factors. Anti-nuclear antibody was borderline-positive (x40), and anti-CL $\beta$ 2GP1 antibody was negative. CH50, C3, and C4 were within normal limits. A biopsy specimen taken from the calf revealed that lymphocytes infiltrated in the upper dermis and invaded into the epidermis (Figure 1D). Fibrin deposition was not found within the capillary walls. Extravasation of erythrocytes in the papillary dermis was seen and associated with interface dermatitis (Figure 1E). While siderophages were unremarkable, iron staining disclosed deposition of hemosiderin (Figure 1F). The diagnosis of Schamberg's disease was made. While she was treated with a topical corticosteroid, the lesions were transiently expanded and improved in the fourth week.

Our case of pigmented purpuric dermatoses shared the clinical features with Schamberg's disease, but it is also characterized by annular configuration, as observed in Majocchi's disease. Notably, it suddenly occurred after SARS-CoV-2 vaccination and subsided in 4 weeks, suggesting that the vaccination triggered the development of the eruption and it was not merely coincidental. A considerable number of cutaneous manifestations of COVID-19 have been reported.<sup>2</sup> Meanwhile, SARS-CoV-2 vaccination evokes urticaria, angioedema, anaphylaxis, COVID arm, morbilliform eruption, erythema multiforme, Stevens-Johnson syndrome, Sweet's disease, leukocytoclastic vasculitis, lupus erythematosus, erythromelalgia, pityriasis rosea, and herpes zoster.<sup>3</sup>

There have been reported a case of pigmented purpuric dermatosis<sup>3</sup> and a case of purpura annularis telangiectodes<sup>4</sup> after the vaccination. They seem to belong to the same category as ours. Accordingly, there has been reported a case of Schamberg-like purpuric eruptions associated with SARS-CoV-2 infection.<sup>5</sup> In addition, Flu vaccine was documented to evoke Majocchi's disease. T cells are considered to be involved in the pathogenesis of Schamberg's disease, SARS-CoV-2 infection, or vaccination may stimulate a certain population of T cells, resulting in the development of the disease.

#### DECLARATION SECTION

Approval of the research protocol: No human participant was involved in this study.

Informed Consent: N/A.


Registry and the Registration NO. of the study/trial: N/A.

Animal studies: N/A.

#### CONFLICT OF INTEREST

The authors declare no conflict of interest.

Hiroki Morimoto MD<sup>1</sup> 

Yasuaki Ogura MD<sup>1,2</sup> 

Masaki Otsuka MD, PhD<sup>1</sup>

Satoshi Hayano MD, PhD<sup>2,3</sup>

Yoshiki Tokura MD, PhD<sup>1,2</sup>

<sup>1</sup>Department of Dermatology & Skin Oncology, Chutoen General Medical Center, Kakegawa, Japan

<sup>2</sup>Allergic Disease Research Center, Chutoen General Medical Center, Kakegawa, Japan

<sup>3</sup>Department of Paediatrics, Chutoen General Medical Center, Kakegawa, Japan

#### Correspondence

Hiroki Morimoo, Department of Dermatology & Skin Oncology, Chutoen General Medical Center, 1-1 Shobugaikae, Kakegawa 436-8555, Japan.

Email: [h.morimoto.0703@gmail.com](mailto:h.morimoto.0703@gmail.com)

#### ORCID

Hiroki Morimoto  <https://orcid.org/0000-0002-0657-8394>

Yasuaki Ogura  <https://orcid.org/0000-0003-3048-2381>

#### REFERENCES

- Ghersetich I, Lotti T, Bacci S, Comacchi C, Campanile G, Romagnoli P. Cell infiltrate in progressive pigmented purpura (Schamberg's disease): immunophenotype, adhesion receptors, and intercellular relationships. *Int J Dermatol*. 1995;34:846–50.
- Gambichler T, Boms S, Susok L, Dickel H, Finis C, Abu Rached N, et al. Cutaneous findings following COVID-19 vaccination: review of world literature and own experience. *J Eur Acad Dermatol Venereol*. 2021;36:172–80. doi:10.1111/jdv.17744
- Atak MF, Farabi B, Kalelioglu MB, Rao BK. Pigmented purpuric dermatosis after BNT162B2 mRNA COVID-19 vaccine administration. *J Cosmet Dermatol*. 2021;21:435–7. doi:10.1111/jocd.14607
- Falkenhain-López D, Gutiérrez-Collar C, Arroyo-Andrés J, Gallego-Gutiérrez I, Rodríguez-Peralto JL, Sánchez-Velázquez A. Widespread purpura annularis telangiectodes following mRNA SARS-CoV-2 vaccine. *J Eur Acad Dermatol Venereol*. 2021;35:e719–21.
- Wollina U. Schamberg-like purpuric eruptions and tonsillitis in mild COVID-19. *Dermatol Ther*. 2020;33:e13766.

#### AUTHOR BIOGRAPHY

**Yoshiki Tokura** is the Founding Editor of the Journal of Cutaneous Immunology. Management of the peer review process, and all editorial decision making, for this article was undertaken by Editor in Chief.