

CORRESPONDENCE

A case of COVID-19 with pernio-like skin lesions and increased red blood cell distribution width

Coronavirus disease 2019 (COVID-19) is related to cutaneous manifestations.¹ Previous reports indicate that pernio-like lesions are cutaneous manifestations of COVID-19.^{1,2} We report a case of pernio-like lesions related to COVID-19.

A 74-year-old Japanese woman with diabetes and hypertension was diagnosed with COVID-19. She was living with her daughter's family, who had also been diagnosed with COVID-19. On illness day 6, she presented to our emergency department with malaise and

worsening shortness of breath (saturation percentage of oxygen in the artery blood 74%). The chest radiograph detected her bilateral interstitial pneumonia, and the treatment of artificial respiration started. Favipiravir, dexamethasone, remdesivir, and empiric antibiotic therapy were administered because of a positive blood culture (*Corynebacterium striatum*, *Klebsiella* species). She was given lactulose, subcutaneous low molecular heparin, and continuous intravenous heparin infusion for prevent COVID-19-related thrombosis. On

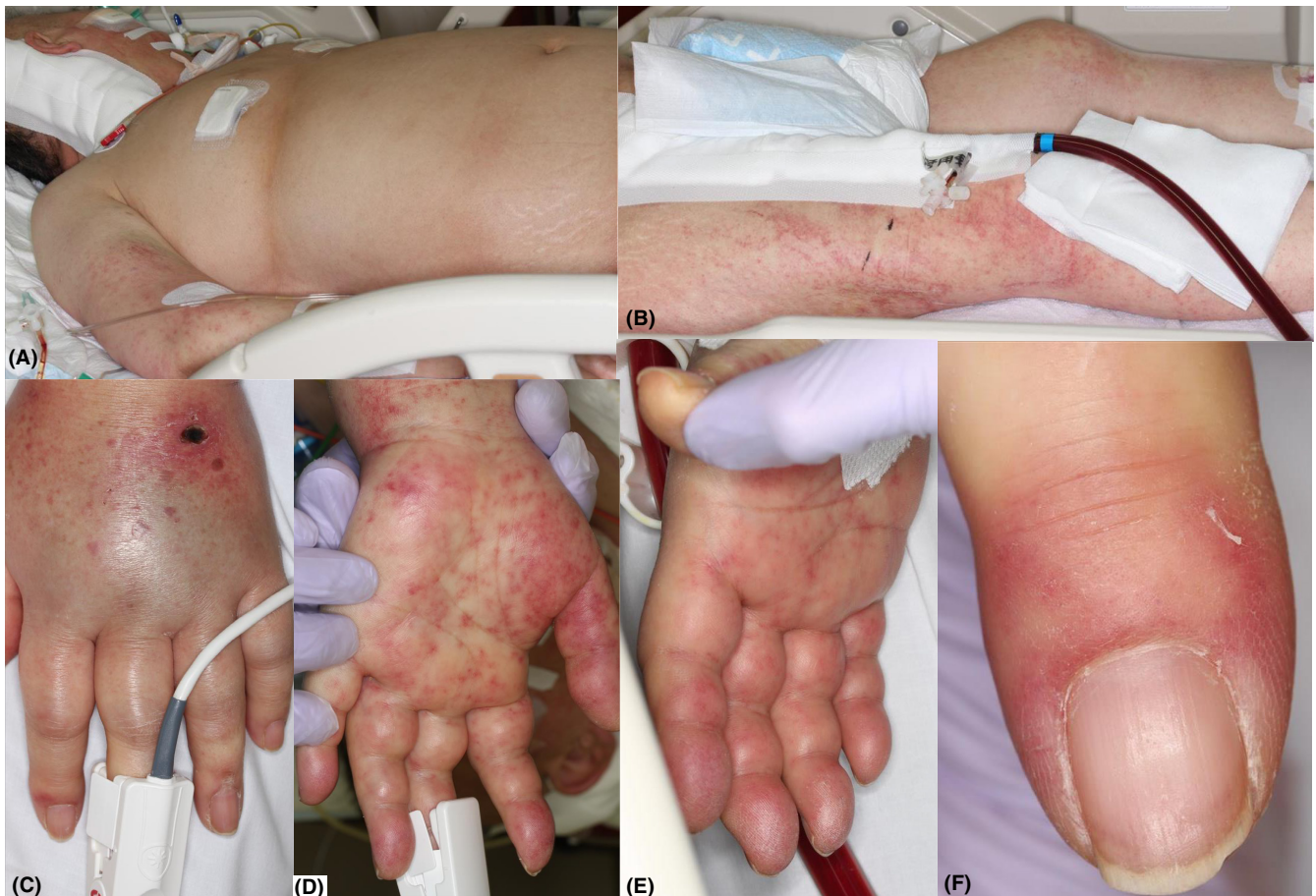

FIGURE 1 On illness day 27, erythema and maculopapular exanthema appeared on the trunk (A), legs (B), and hands (C). A hemorrhagic rash on the hands (D) and pernio-like lesions were seen on her fingers (E, F) and toes.

This is an open access article under the terms of the [Creative Commons Attribution-NonCommercial](https://creativecommons.org/licenses/by-nc/4.0/) License, which permits use, distribution and reproduction in any medium, provided the original work is properly cited and is not used for commercial purposes.

© 2022 The Authors. *Journal of Cutaneous Immunology and Allergy* published by John Wiley & Sons Australia, Ltd on behalf of The Japanese Society for Cutaneous Immunology and Allergy.

illness day 13, her breathing became worse. Extracorporeal membrane oxygenation was started. On illness day 25, erythema was seen on her body. On illness day 27, erythema and maculopapular exanthema appeared on her trunk (Figure 1A), legs (Figure 1B), and hands (Figure 1C). A hemorrhagic rash appeared on her hands (Figure 1D). Pernio-like lesions were seen on her fingers (Figure 1E,F) and toes. Laboratory inspection clarified a normal white blood cell count (5860/mm), normal liver and kidney function, decreased hemoglobin (10.1 g/dl; normal range: 10.6–14.4 g/dl), hematocrit (31.5%; normal range: 32.1%–42.7%), platelet count (45,000/mm; normal range: 13,800–309,000/mm), increased C-reactive protein (CRP, 10.56 mg/dl; normal range <0.3 mg/dl), lactate dehydrogenase (LD, 346 U/L; normal range: 119–229 U/L), fibrinogen-fibrin degradation product (FDP, 113.8 µg/ml; normal range <5.0 µg/ml), dimerized plasmin fragment D (D-dimer, 55.5 µg/ml; normal range <1.0 µg/ml), and red blood cell distribution width (RDW, 16.2%; normal range 11.5%–13.8%). Over the following days, gradual spontaneous improvement of skin lesions occurred. However, she became the cerebral infarction and died on illness day 44.

Previous studies found that 318 of 505 (63%) patients with dermatologic symptoms related to COVID-19 had pernio-like lesions.³ Pernio-like lesions were sole symptoms in the 55% of patients.³ Retiform purpura presented entirely in inpatients.¹ Mechanisms of COVID-19 coagulopathy have been proposed. In a hypercoagulable situation, the crosstalk between the inflammatory and hemostatic systems may advance for thrombosis in COVID-19.⁴ Heparin resistance was observed in patients with COVID-19 infectious disease of the serious case.⁴

Elevated RDW is associated with an increased risk for mortality from heart disease, pulmonary disease, sepsis, influenza, and cancer.⁵ RDW related to the death rate in Cox proportional hazards models adjusted for age, D-dimer level, and common comorbidities such as diabetes and hypertension.⁵ Patients whose RDW increased during hospitalization had higher mortality compared with those whose RDW did not change.⁵

In our case, skin manifestations of sepsis with DIC or heparin-induced thrombocytopenia need to be considered. However, cutaneous manifestations, RDW, and levels of LD and D-dimer might be useful biomarkers to improve the efficiency of information input work related to symptoms of the determination of triage of patients with COVID-19.

ACKNOWLEDGMENTS

This work was supported in part by the 2022 Hirosaki University Research Support System.

CONFLICT OF INTEREST

The authors declare no conflicts of interest.

DECLARATION SECTION


Approval of the research protocol: This study was approved by the Committee of Medical Ethics of Hirosaki University Graduate School of Medicine in Aomori, Japan. The patient was registered to the

trial was registered in the University Hospital Medical Information Network (UMIN) (Reservation No. UMIN000041301) by approved by the Committee of Medical Ethics of Hirosaki University Graduate School of Medicine in Aomori, Japan.

Informed Consent: Written informed consent was obtained from the patient's husband.

Registry and the Registration No. of the study/trial: 21,928.

Animal Studies: N/A.

Satoko Minakawa MD, PhD^{1,2} 

Yasushi Matsuzaki MD, PhD¹

Akari Terada MD¹

Shu Ogasawara PhD²

Yuki Nishiya MD, PhD³

Jin Irie MD, PhD³

Yoshiya Ishizawa MD, PhD³

Hiroyuki Hanada MD, PhD³

Daisuke Sawamura MD, PhD¹

¹Department of Dermatology, Hirosaki University Graduate School of Medicine, Aomori, Japan

²Department of Clinical Laboratory, Advanced Emergency and Disaster Medical Center, Hirosaki University Hospital, Aomori, Japan

³Advanced Emergency and Disaster Medical Center, Hirosaki University Hospital, Aomori, Japan

Correspondence

Daisuke Sawamura, Department of Dermatology, Hirosaki University Graduate School of Medicine, 5 Zaifu-cho, Hirosaki, Aomori 036-8562, Japan.
Email: smartdai@hirosaki-u.ac.jp

ORCID

Satoko Minakawa  <https://orcid.org/0000-0001-5933-3377>

REFERENCES

- Freeman EE, McMahon DE, Lipoff JB, Rosenbach M, Kovarik C, Desai SR, et al. The spectrum of COVID-19-associated dermatologic manifestations: an international registry of 716 patients from 31 countries. *J Am Acad Dermatol*. 2020;83:1118–29.
- Sachdeva M, Gianotti R, Shah M, Bradanini L, Tosi D, Veraldi S, et al. Cutaneous manifestations of COVID-19: report of three cases and a review of literature. *J Dermatol Sci*. 2020;98:75–81.
- Freeman EE, McMahon DE, Lipoff JB, Rosenbach M, Kovarik C, Takeshita J, et al. American Academy of Dermatology ad hoc task force on COVID-19 a case series of 318 patients from 8 countries. *J Am Acad Dermatol*. 2020;83:486–92.
- Chowdhry E, Moshman J, Carroll S. A case of COVID-19 related coagulopathy complications and heparin resistance. *Cureus*. 2021;13:e18265. <https://doi.org/10.7759/cureus.18265>
- Foy BH, Carlson JCT, Reinertsen E, Padros IVR, Pallares Lopez R, Palanques-Tost E, et al. Association of red blood cell distribution width with mortality risk in hospitalized adults with SARS-CoV-2 infection. *JAMA Netw Open*. 2020;3:e2022058.