


CASE STUDY

Autosomal recessive hyper-IgE syndrome due to DOCK8 deficiency: An adjunctive role for omalizumab

Kim Han Nguyen MD^{1,2} | Quynh Anh Nguyen MD, MSc² | Mai Hoang Tran MSc³ |
Thu Thuy Can BS² | Mai Thi Vu MD, MSc² | Nam Sy Vo PhD^{3,4} | Hieu Chu Chi PhD⁵ |
Sheryl van Nunen MBBS, MM(Sleep Medicine), FRACP^{6,7} | Dinh Van Nguyen MD, PhD^{1,2} 

¹College of Health Sciences, VinUniversity, Hanoi, Vietnam

²Vinmec Healthcare System, Hanoi, Vietnam

³Vingroup Big Data Institute, Hanoi, Vietnam

⁴College of Engineering and Computer Science, VinUniversity, Hanoi, Vietnam

⁵Center of Allergology and Clinical Immunology, Bach Mai Hospital, Hanoi, Vietnam

⁶Northern Clinical School, Sydney Medical School, Faculty of Medicine and Health, The University of Sydney, Sydney, New South Wales, Australia

⁷Clinical Immunology and Allergy, Northern Beaches Hospital, Faculty of Medicine and Health, Macquarie University, Sydney, New South Wales, Australia

Correspondence

Dinh Van Nguyen, Clinical Immunology and Allergy, Allergy and Clinical Immunology Unit, Internal Medicine Department, Vinmec Healthcare System, Hanoi, Vietnam.
Email: drdinh.allergist@gmail.com

Funding information

Vingroup Big Data Institute, Hanoi, Vietnam

Abstract

Autosomal recessive hyper-IgE syndrome (AR-HIES) is a rare primary immunodeficiency disorder characterized by high serum IgE levels, recurrent viral skin infections, severe allergies, and early-onset malignancies, associated with mutations in the gene encoding the dedicator of cytokinesis 8 protein (DOCK8). We report a rare case of AR-HIES with DOCK8 deficiency in a young Japanese male with a past medical history of chronic atopic dermatitis, severe food allergies, and severe herpes simplex virus infection. Treatment was successfully based on infection management, skincare, and dietary elimination. In addition, anti-IgE therapy with omalizumab was the target treatment for this syndrome.

KEYWORDS

AR-HIES, DOCK8 deficiency, immunodeficiency disorder, omalizumab, recurrent viral infection

Kim Han Nguyen, Quynh Anh Nguyen, and Mai Hoang Tran equally contributed.

This is an open access article under the terms of the [Creative Commons Attribution-NonCommercial](https://creativecommons.org/licenses/by-nc/4.0/) License, which permits use, distribution and reproduction in any medium, provided the original work is properly cited and is not used for commercial purposes.

© 2022 The Authors. *Journal of Cutaneous Immunology and Allergy* published by John Wiley & Sons Australia, Ltd on behalf of The Japanese Society for Cutaneous Immunology and Allergy.

1 | INTRODUCTION

Hyper-IgE syndromes (HIES) are rare primary immunodeficiency diseases (PID) comprising AD-HIES and AR-HIES.¹ Autosomal dominant hyper-IgE syndrome (AD-HIES) is caused by heterozygous, dominant-negative missense mutations in *STAT3*. Patients with AD-HIES often have *Staphylococcus aureus* infections in skin and lungs, and may also have decreased numbers of Th17 cells, contributing to susceptibility to mucocutaneous candidiasis.¹ Autosomal recessive hyper-IgE syndrome (AR-HIES), however, is caused by homozygous or compound heterozygous loss-of-function mutations in *DOCK8* (dedicator of cytokinesis 8), *TYK2* (tyrosine kinase 2), *PGM3* (phosphoglucomutase 3), serine peptidase inhibitor Kazal type 5 (*SPINK5*), or zinc finger 431 (*ZNF431*).²⁻⁴ The most common gene defect is in *DOCK8*, found in 70% of AR-HIES patients.³ AR-HIES sufferers often present with recurrent viral infections, severe allergies, and early-onset malignancies.⁴ This report, describing a patient with AR-HIES due to *DOCK8* deficiency, is the first from Vietnam.

2 | CASE REPORT

A 30-year-old Japanese man, resident in Vietnam, presented with a week-long history of a vesicular eruption, high fever, and chills. These pruritic, painful lesions in the right axilla quickly spread to the chest, abdomen, back, and arms. He had a similar episode 10 years ago, without fever and chills. No clear-cut diagnosis was reached at that time, topical medication resolved the lesions within a month. Chronic atopic dermatitis and severe food allergies were present.

There was no history of recent travel, medication use, or intravenous drug use. His family history was unremarkable.

Vital signs were normal. Multiple axillary lymph nodes were found bilaterally (size 2×3 cm, tender and mobile). Multiple 1–2 mm vesicles and pustules on an erythematous base were noted over chest, abdomen, back, and arms (shown in Figure 1A,B). He lacked the characteristic facial appearance of AD-HIES (broad nose, deep-set eyes with a prominent forehead). The oral mucosa was normal. There was no thrush, vesicles, or retained primary teeth.

Immunologic assessment suggested AR-HIES with elevated serum IgE levels (33,554 IU/ml), hypereosinophilia (1000 cell/mm³), decreased circulating T cells (TCD3 260 Cell/μl, TCD4 184 Cell/μl, TCD8 72 Cell/μl), low serum IgM levels (Table E1), and EUROLINE Atopy Screening testing detected high levels of specific IgE against several allergens (shown in Figure 2). Screening for malignancy (including CT-scan and serological markers) showed no significant abnormality.

Peripheral blood was collected for DNA extraction by DNA Blood Mini Kit (Qiagen) before whole-exome sequencing by Novaseq6000 150PE platform (Illumina) with SureSelect Human Whole Exome V6 Capture Kit (Agilent) for library preparation. The output data of 14Gb with an average sequencing depth on target of 139X and a Q30 of base quality of 93.01% were used for variant calling by GATK (Genome Analysis Toolkit) best practices™ pipeline software (Broad Institute of MIT and Harvard). Following genomic variant detection, annotation of variants with the tool ANNOVAR (ANNOtate VARIation, Open source software, <https://annovar.openbioinformatics.org/>) in multiple aspects was used, including protein-coding changes, g nomic regions affected by the variants, allele frequency,

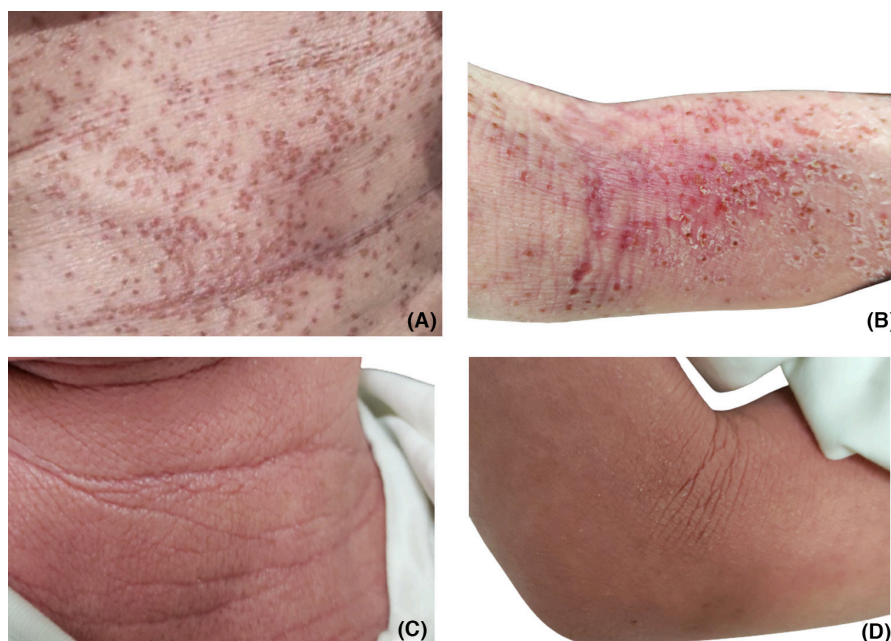


FIGURE 1 Patient's skin lesions before (A, B) and after treatment (C, D). (A–B) Multiple 1–2 mm vesicles and pustules on an erythematous base were noted over the chest, abdomen, back, and arms. Eczematous lesions of dry, flaky, erythematous, and lichenified skin were present over flexural areas. (C–D) Rapid improvement in the condition of the skin was noted. EASI score had decreased from 22.7 (before treatment) to 10.8 (after treatment).

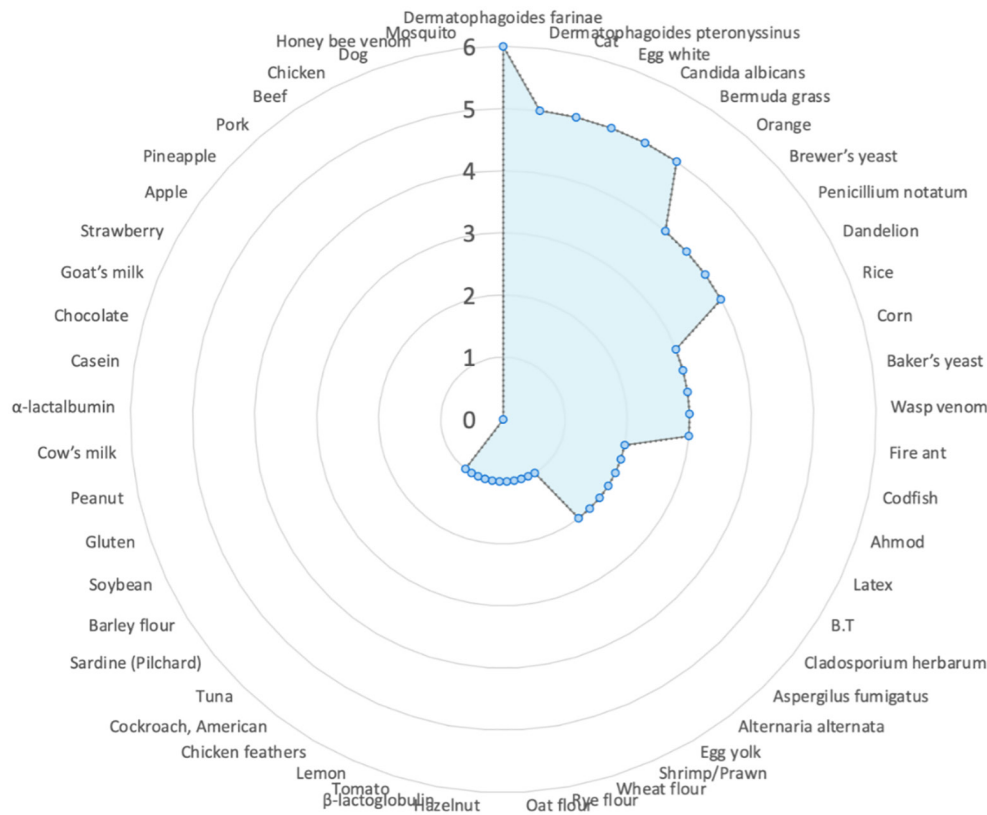


FIGURE 2 Specific IgE profiling. This patient has had severe food allergies from childhood. The EUROLINE Atopy Screening testing detected high levels of specific IgE against several allergens.

and deleteriousness prediction.^{1,5} Main databases used were RefSeq, Gencode, 1000 Human Genome, Exome Aggregation Consortium (ExAC), gnomAD, dbSNP, COSMIC, OMIM, GWAS Catalog, HGMD, and Gene Ontology and KEGG.

Clinical and laboratory findings in our patient led us to focus on the gene set related to AR-HIES where abnormalities have been reported previously (including DOCK8, ZNF431, TYK2, PGM3, CARD11, and SPINK5).⁶ Consistent with the patient's phenotype, there was no mutation detected in STAT3. However, two missense variants were found in the DOCK8 gene at c.289C>A (p.Pro97Thr) and c.5908G>C (p.Ala1970Pro) in exon 3 and 45 of 48, respectively. Interestingly, SPINK5 which is highly associated with Comel-Netherton syndrome has five missense mutations recorded.²

Supportive treatment was commenced with methylprednisolone 40mg/day IV for 5 days and then switched to oral methylprednisolone 16mg/day for 1 week, acyclovir 500mg q4hr for 5 days, and moisturizer. Trimethoprim/sulfamethoxazole 960mg orally twice daily for 5 days was also administered because of *S. aureus* superinfection suspicion. These initial treatments provided rapid improvement of skin lesions (especially virus-induced vesicles) after 1 week. Introduction of omalizumab 300mg by subcutaneous injection every 2 weeks and dietary elimination (egg) led to further significant clinical improvement and decrease in total IgE (to 30,134IU/ml) without side effects (shown in Figure 1C,D). EASI score decreased from 22.7 (pre-treatment) to 10.8 (after 3 months).

3 | DISCUSSION

AR-HIES is caused by homozygous, recessive mutations in one of the genes: DOCK8 (dedicator of cytokinesis 8), TYK2 (Tyrosine kinase 2), PGM3 (Phosphoglucomutase 3), SPINK5 (Serine Peptidase Inhibitor Kazal type 5), and ZNF341 (Zinc Finger 341; shown in Figure 3).^{4,7,8} Typically, patients have recurrent otitis media, sinusitis, pneumonia, recurrent *Staphylococcus aureus* skin infections, otitis externa; recurrent, severe herpes simplex virus or herpes zoster infections; extensive and persistent molluscum contagiosum; and Human papillomavirus infections.⁷ Commonly, bacterial infections occur (*Streptococcus pneumoniae*, *Haemophilus influenzae*, *Pneumocystis jiroveci*, *Staphylococcus aureus*, and *Salmonella typhi*); and adenovirus, herpes simplex, herpes zoster, and varicella virus infections. Most patients have severe atopy with anaphylaxis; atopic dermatitis, severe and extensive food or environmental allergies, asthma or reactive airway disease, eosinophilic esophagitis, or lung disease.⁸ AR-HIES patients have an increased risk of squamous cell carcinoma, T-cell lymphoma (one report), and leukemia.⁸

Laboratory tests often show markedly elevated serum IgE levels, hypereosinophilia, low numbers of T and B cells, low serum IgM levels, and variable IgG antibody responses. In genetic analyses, DOCK8 defects are found in 72% of AR-HIES patients.³ Novel homozygous or compound heterozygous deletions and point mutations in the gene encoding the dedicator of cytokinesis 8 protein (DOCK8) lead to the absence of DOCK8 protein in lymphocytes.⁸

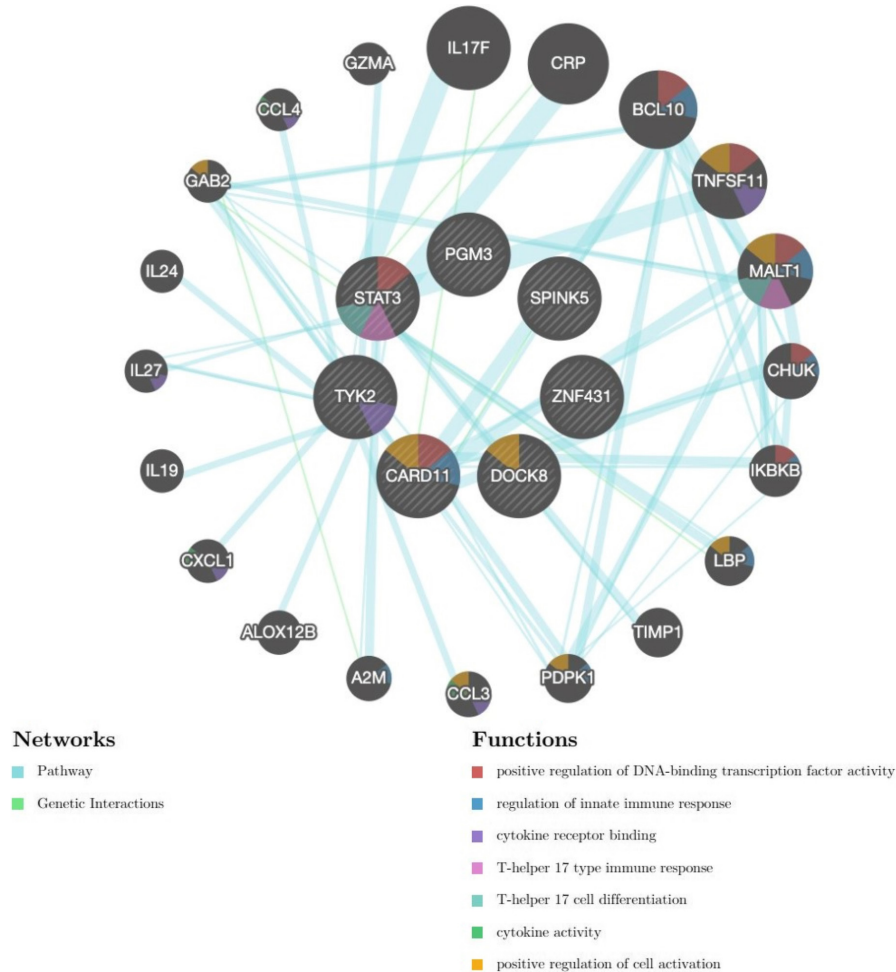


FIGURE 3 Networks and functional pathways of key genes involved in HIES. The cross-talk among susceptible genes that have been determined in HIES. AD-HIES is caused by heterozygous, dominant-negative missense mutations in STAT3. AR-HIES caused by homozygous, recessive mutations in one of the genes: DOCK8 (dedicator of cytokinesis 8), TYK2 (Tyrosine kinase 2), PGM3 (Phosphoglucomutase 3), SPINK5 (Serine Peptidase Inhibitor Kazal type 5), and ZNF341 (Zinc Finger 341).

Co-existence of a homozygote mutation at c.289C>A and heterozygote mutation at c.5908G>C in this patient suggests a novel function between those mutations in DOCK8 deficiency with AR-HIES. Further study of molecular characteristics correlated with the phenotype of the patient's family members might validate the association of DOCK8 mutation with AR-HIES.

Since there are no data from randomized therapeutic trials, due to the rarity of HIES, management is based upon observational data and clinical experience. Management goals are to (1) control the pruritus and eczematoid dermatitis and (2) prevent the occurrence of severe systemic infections.

Omalizumab (humanized recombinant monoclonal antibody against IgE) reduces serum IgE levels and FcεRI receptor expression on key cells in the inflammatory cascade^{9,10} Bard et al.¹¹ used it firstly to successfully treat severe recalcitrant eczematous dermatitis in the setting of HIES. Other studies have also reported clinical improvements in patients with HIES.¹²⁻¹⁴

Due to the high serum IgE level, severe recalcitrant eczema with food allergy triggers and the need for prolonged systemic

corticosteroid treatment in our patient, omalizumab was employed as an adjunctive anti-inflammatory therapy to control the dermatitis and thus reduce the infection risk. Treatment with omalizumab was associated with a beneficial effect upon the dermatitis. Prospective studies and long-term follow-up are required, however, to confirm the efficacy of omalizumab in HIES.

4 | CONCLUSIONS

This is the first report of a typical case of DOCK8 deficiency syndrome in Vietnam. In clinical practice, a patient with recurrent viral infections, severe allergies, eosinophilia, and markedly elevated IgE should be investigated for AR-HIES and for mutations in the DOCK8 gene. Supportive treatment based on management of infection, skin care, and elimination of dietary allergens is essential; however, anti-IgE therapy with omalizumab should be considered as an adjunctive treatment for this syndrome.

AUTHOR CONTRIBUTIONS

Dinh Van Nguyen conceptualized the study and involved in project administration. Mai Hoang Tran, Anh Quynh Nguyen, Han Kim Nguyen, Thuy Thu Can, Dinh Van Nguyen involved in formal analysis. Han Kim Nguyen, Anh Quynh Nguyen; Nam Sy Vo, Dinh Van Nguyen investigated the study. Anh Quynh Nguyen; Mai Thi Vu, Hieu Chi Chu, Dinh Van Nguyen contributed to the clinical treatment. Han Kim Nguyen, Dinh Van Nguyen, Sheryl van Nunen involved in writing—original draft. Dinh Van Nguyen, Sheryl van Nunen involved in writing—review and editing. All authors were involved in the acquisition, analysis, and interpretation of empirical data, worked on drafting and critical revision of the manuscript for important intellectual content, and approved the final version.

FUNDING INFORMATION

This work was supported by Vingroup Big Data Institute, Hanoi, Vietnam for whole-exome sequencing.

CONFLICT OF INTEREST

The authors have no conflicts of interest to declare.

DECLARATION SECTION

Approval of the research protocol: The patient and his family have given their written informed consent to publish his details of his medical case and any accompanying images. Information revealing the subject's identity is to be avoided.

Informed consent: Written informed consent was obtained from the patient for publication of this case report and any accompanying images.

Registry and the Registration No. of the study/trial: This study was reviewed and approved by Vinmec Healthcare System-VinUniversity institutional ethical review board for biomedical research: No. 165/2021/QD-VMC.

Animal Studies: N/A.

ORCID

Dinh Van Nguyen  <https://orcid.org/0000-0002-5675-0850>

REFERENCES

- Schimke LF, Sawalle-Belohradsky J, Roesler J, Wollenberg A, Rack A, Borte M, et al. Diagnostic approach to the hyper-IgE syndromes: immunologic and clinical key findings to differentiate hyper-IgE syndromes from atopic dermatitis. *J Allergy Clin Immunol*. 2010;126(3):611–617.e1.
- Kato A, Fukai K, Oiso N, Hosomi N, Murakami T, Ishii M. Association of SPINK5 gene polymorphisms with atopic dermatitis in the Japanese population. *Br J Dermatol*. 2003;148(4):665–9.
- Alsum Z, Hawwari A, Al-Hifi S, Borrero E, Khalak H, Ades N, et al. Clinical and molecular characterization of autosomal recessive hyper IgE Syndrome in Saudi Arabia. *J Allergy Clin Immunol*. 2012;129(2):AB83.
- Liza M, Gaurav D, Prasenjeet M, Swapna J, Binodini B. Autosomal-recessive hyper-IgE syndrome. *Indian J Dermatol*. 2018;63(1):79–81.
- Wang K, Li M, Hakonarson H. ANNOVAR: functional annotation of genetic variants from high-throughput sequencing data. *Nucleic Acids Res*. 2010;38(16):e164.
- Al-Shaikhly T, Ochs HD. Hyper IgE syndromes: clinical and molecular characteristics. *Immunol Cell Biol*. 2019;97(4):368–79.
- Freeman AF, Holland SM. Clinical manifestations, etiology, and pathogenesis of the hyper-IgE syndromes. *Pediatr Res*. 2009;65(5 Part 2):32R–7R.
- Zhang Q, Davis JC, Lamborn IT, Freeman AF, Jing H, Favreau AJ, et al. Combined immunodeficiency associated with *DOCK8* mutations. *N Engl J Med*. 2009;361(21):2046–55.
- Navinés-Ferrer A, Serrano-Candelas E, Molina-Molina GJ, Martín M. IgE-related chronic diseases and anti-IgE-based treatments. *J Immunol Res*. 2016;2016:1–12.
- Stokes JR, Casale TB. The use of anti-IgE therapy beyond allergic asthma. *J Allergy Clin Immunol Pract*. 2015;3(2):162–6.
- Bard S, Paravisini A, Avilés-Izquierdo JA, Fernandez-Cruz E, Sánchez-Ramón S. Eczematous dermatitis in the setting of hyper-IgE syndrome successfully treated with Omalizumab. *Arch Dermatol*. 2008;144(12):1662–3.
- Chularojanamontri L, Wimoolchart S, Tuchinda P, Kulthanan K, Kiewjoy N. Role of omalizumab in a patient with hyper-IgE syndrome and review dermatologic manifestations. *Asian Pac J Allergy Immunol*. 2009;27(4):233–6.
- Cortázar-Benítez LF, Rojas Sotelo RM, Vargas-Viveros P, Hurtado-Monroy R, Romo Aguirre C, Valenzuela Tamariz J, et al. Hyper Immunoglobulin E Syndrome (HIES): report of a new case treated with omalizumab and dexametason. *Blood*. 2011;118(21):4934–4.
- Marcotte G. Omalizumab therapy for hyper-IgE syndrome. *J Allergy Clin Immunol*. 2008;121(2):S88.

SUPPORTING INFORMATION

Additional supporting information can be found online in the Supporting Information section at the end of this article.

How to cite this article: Nguyen KH, Nguyen QA, Tran MH, Can TT, Vu MT & Vo NS et al. Autosomal recessive hyper-IgE syndrome due to *DOCK8* deficiency: An adjunctive role for omalizumab. *J Cutan Immunol Allergy*. 2022;5:222–226. <https://doi.org/10.1002/cia2.12273>