

CORRESPONDENCE

Erythema annulare centrifugum in the setting of COVID-19 infection: A case report and literature review

Erythema annulare centrifugum (EAC) is a figurate papulo-erythema following a self-limiting course, caused by a variety of underlying factors. Skin manifestations associated with COVID-19 infection considerably vary,¹ and sometimes exhibit clinically ambiguous appearance compared to the original disease image (e.g., erythema multiforme-like, Gianotti-Crosti-like, pernio-like, and livedo-like eruptions),²⁻⁵ but COVID-19-associated EAC or similar eruption has rarely been reported to date.

An otherwise healthy 49-year-old Japanese male who had a 2-week history of malaise was diagnosed with COVID-19 by a positive reverse transcription-polymerase chain reaction for SARS-CoV-2. He had never received the SARS-CoV-2 vaccine. The next day after receiving 200mg/day of remdesivir intravenously, asymptomatic erythema appeared suddenly on the lumbar and extremities. Physical

examination showed non-coalescent edematous erythema with partially defined borders on the lumbar and legs (Figure 1A,B). A routine laboratory test and screening for autoimmune diseases showed no abnormal findings, except for atypical lymphocytes and elevated CRP. The chest CT showed diffuse frosted shadows in both lungs suggestive of COVID-19. Skin biopsy revealed focal spongiosis, vacuolar changes along with the dermo-epidermal junction, and densely packed inflammatory cell infiltrates around blood vessels in the superficial dermis (Figure 1C). The infiltrating cells are composed of predominant lymphocytes and scant eosinophils with a "coat-sleeve"-like appearance (Figure 1D). The clinicopathological findings raised the diagnosis of EAC. After discontinuation of remdesivir, he was treated with topical steroids and oral antihistamine, providing successful remission of the skin lesion by 1 month, as the

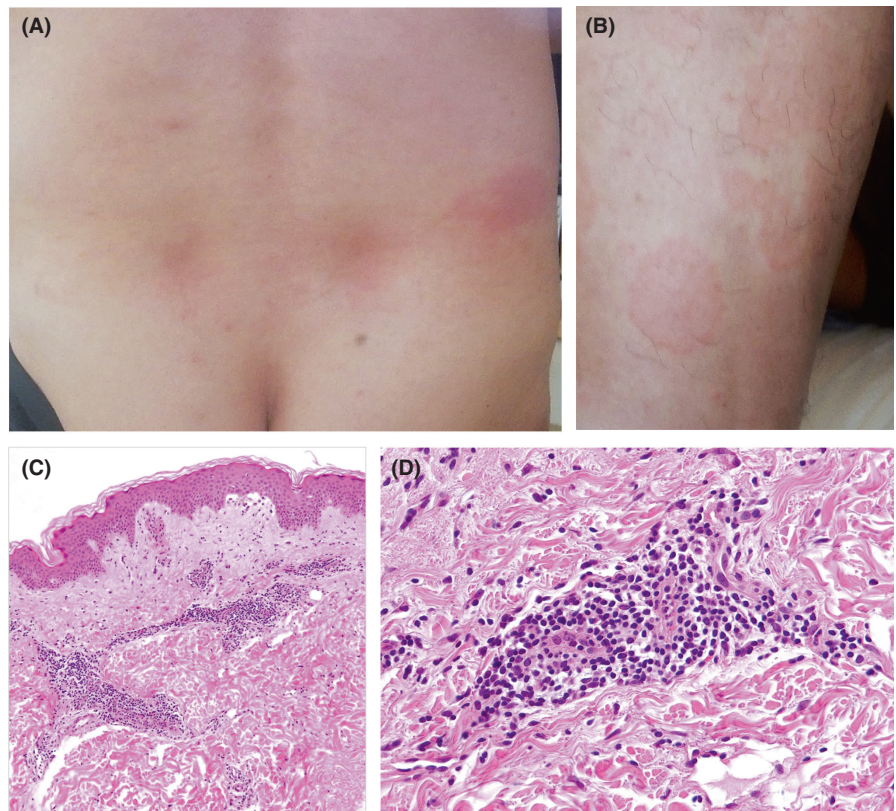


FIGURE 1 Clinicopathological presentation. Skin manifestation showing annular erythema with relatively defined border, some of which coalesced and enlarged, on the lumbar (A) and lateral aspect of thighs (B). Clear clinical pictures could not be taken due to the facility's infection control rules for COVID-19. The lesional skin pathology showing dense lymphocytic infiltration with scant eosinophils (C, $\times 20$, H&E; D, $\times 200$, H&E)

This is an open access article under the terms of the [Creative Commons Attribution-NonCommercial](https://creativecommons.org/licenses/by-nc/4.0/) License, which permits use, distribution and reproduction in any medium, provided the original work is properly cited and is not used for commercial purposes.

© 2022 The Authors. *Journal of Cutaneous Immunology and Allergy* published by John Wiley & Sons Australia, Ltd on behalf of The Japanese Society for Cutaneous Immunology and Allergy.

COVID-19-related symptoms lessened. The skin lesion has never recurred thereafter.

Most cases with EAC are clinically idiopathic, although the current concept regarding the disease pathogenesis suggests a delayed-type hypersensitivity to various antigens, including viral, bacterial, or fungal infections, drugs, foods, malignancy or other systemic diseases.⁶ This is supported by evidence that the skin manifestation of EAC is alleviated by treatment of the underlying disease. EAC associated with viral infection has been reported to be triggered by various viruses, such as EB virus, poxvirus, HIV, varicella-zoster virus, and influenza virus, and is mostly transient like our case or displays a fluctuating skin lesion in parallel with the viral disease activity.

To our knowledge, there have been only four case reports, including ours, for EAC encountered in association with COVID-19 infection; one of whom resolved with oral doxycycline,⁷ and three others improved with topical steroids and/or antihistamine.^{8,9} Except one child case,⁸ their skin lesions appeared about 1 week after the onset of COVID-19 infection and disappeared within 1 month, suggesting the consequence of viral infection itself and/or preceded antiviral therapy. Except our case, however, the remaining three cases have received neither antiviral therapy including remdesivir nor any of drugs. COVID-19 infection may cause impaired immune response with dysregulation of proinflammatory cytokines, particularly tumor necrosis factor- α ,¹⁰ thus implicating the underlying immunopathogenic similarity between COVID-19 infection and EAC. EAC associated with COVID-19, therefore, remains presumptive further awaiting similar case series to update evidence for the pathogenesis and response to treatment, and also proper recognition of dermatologists.

KEYWORDS

cytokines, SARS-CoV-2, skin manifestation, Viral infection

CONFLICT OF INTEREST

The authors declare no conflict of interest.

DECLARATION SECTION

Approval of the research protocol: No human participant was involved in this study.


Informed consent: N/A.

Registry and the Registration No. of the study/trial: N/A.

Animal Studies: N/A.

Misako Fujisaki MD¹

Takumi Hasegawa MD¹

Noritaka Oyama MD, PhD¹ 

Koji Yamaoka MD²

Masaki Anzai MD, PhD²

Minoru Hasegawa MD, PhD¹

¹Department of Dermatology, Faculty of Medical Sciences,
University of Fukui, Fukui, Japan

²Third Department of Internal Medicine, Faculty of Medical
Sciences, University of Fukui, Fukui, Japan

Correspondence

Noritaka Oyama, Department of Dermatology, Faculty
of Medical Sciences, University of Fukui, 23-3 Matsuoka-
Shimoaizuki, Eiheiji, Fukui 910-1193, Japan.

Email: norider@u-fukui.ac.jp

ORCID

Noritaka Oyama  <https://orcid.org/0000-0003-4934-5205>

REFERENCES

- Sachdeva M, Gianotti R, Shah M, Bradanini L, Tosi D, Veraldi S, et al. Cutaneous manifestations of COVID-19: Report of three cases and a review of literature. *J Dermatol Sci*. 2020;98:75–81.
- Jimenez-Cauhe J, Ortega-Quijano D, Carretero-Barrio I, Suarez-Valle A, Saceda-Corralo D, Moreno-Garcia Del Real C, et al. Erythema multiforme-like eruption in patients with COVID-19 infection: clinical and histological findings. *Clin Exp Dermatol*. 2020;45:892–5.
- Berná-Rico ED, Álvarez-Pinheiro C, Burgos-Blasco P, Selda-Enríquez G, Azcárraga-Llobet C, Fernández-Guarino M, et al. A Gianotti-Crosti-like eruption in the setting of SARS-CoV-2 infection. *Dermatol Ther*. 2021;34:e15071.
- García-Lara G, Linares-González L, Ródenas-Herranz T, Ruiz-Villaverde R. Chilblain-like lesions in pediatrics dermatological outpatients during the COVID-19 outbreak. *Dermatol Ther*. 2020;33:e13516.
- Rekhtman S, Tannenbaum R, Strunk A, Birabaharan M, Wright S, Grbic N, et al. Eruptions and related clinical course among 296 hospitalized adults with confirmed COVID-19. *J Am Acad Dermatol*. 2021;84:946–52.
- Kim KJ, Chang SE, Choi JH, Sung KJ, Moon KC, Koh JK. Clinicopathologic analysis of 66 cases of erythema annulare centrifugum. *J Dermatol*. 2002;29:61–7.
- Montinari M, Atzori L, Valdevit S, Rongioletti F. Erythema annulare centrifugum with anosmia and ageusia in a SARS-CoV-2 exposed patient successfully treated with doxycycline. *Int J Dermatol*. 2021;60:384–6.
- Cakir A, Bostan E, Kaymaz E. Erythema annulare centrifugum following SARS-CoV-2 infection in a pediatric patient. *Int J Dermatol*. 2022. <https://doi.org/10.1111/ijd.16194>
- Setó-Torrent N, Altemir A, Iglesias-Sancho M, Fernández-Figueras MT. Erythema annulare centrifugum triggered by SARS-CoV-2 infection. *J Eur Acad Dermatol Venereol*. 2022;36:e4–6.
- Minni J, Sarro R. A novel therapeutic approach to erythema annulare centrifugum. *J Am Acad Dermatol*. 2006;54:S134–5.