


ORIGINAL ARTICLE

Management of early hepatic artery thrombosis following living-donor liver transplantation: feasibility, efficacy and potential risks of endovascular therapy in the first 48 hours post-transplant—a retrospective cohort study

Omar Abdelaziz¹, Ayman M. A. Osman² , Karim A. Hosny³, Sally Emad-Eldin¹, Dalia K. Serour¹ & Mohamed Mostafa¹

¹ Department of Diagnostic and Interventional Radiology, Faculty of Medicine, Cairo University, Cairo, Egypt

² Department of General Surgery, Unit of Hepatobiliary Surgery, Faculty of Medicine, Cairo University, Cairo, Egypt

³ Department of General Surgery, Unit of Vascular Surgery, Faculty of Medicine, Cairo University, Cairo, Egypt

Correspondence

Ayman M. A. Osman, MD, MRCS (Eng), Assistant Professor of General and Hepato-pancreatico-biliary Surgery, Department of General Surgery, Faculty of Medicine – Cairo University, Postcode: 11562, Cairo, Egypt.

Tel.: +2 0106 6835 810;

e-mails: aymanhady@cu.edu.eg; aymanhady@gmail.com

SUMMARY

This retrospective cohort study aims to review our 18-year experience with early hepatic artery thrombosis (e-HAT) following living-donor liver transplantation (LDLT), as well as to assess the feasibility, efficacy and potential risks of endovascular management of e-HAT in the first 48 hours (hrs) post-LDLT. Medical records of 730 patients who underwent LDLT were retrospectively reviewed. In all cases who had developed e-HAT, treatment modalities employed and their outcomes were evaluated. Thirty-one patients developed e-HAT(4.2%). Definite technical success and 1-year survival rates of surgical revascularization[11/31 cases(35.5%)] were 72.7% & 72.7%, whereas those of endovascular therapy[27/31 cases(87.1%)] were 70.4% & 59.3%, respectively. Endovascular therapy was carried out in the first 48hrs post-transplant in 9/31 cases(29%)[definite technical success:88.9%, 1-year survival:55.6%]. Four procedure-related complications were reported in 3 of those 9 cases(33.3%). In conclusion, post-LDLT e-HAT can be treated by surgical revascularization or endovascular therapy, with comparable results. Endovascular management of e-HAT in the first 48hrs post-LDLT appears to be feasible and effective, but is associated with a relatively higher risk of procedure-related complications, compared to surgical revascularization. Hence, it can be reserved as a second-line therapeutic option in certain situations where surgical revascularization is considered futile, potentially too complex, or potentially more risky.

Transplant International 2021; 34: 1134–1149

Key words

early hepatic artery thrombosis, efficacy, endovascular management, feasibility, first 48 hours, living-donor liver transplantation

Received: 6 September 2020; Revision requested: 2 October 2020; Accepted: 21 January 2021;

Published online: 14 April 2021

Introduction

Hepatic artery thrombosis (HAT) is the most frequently encountered vascular complication following orthotopic

liver transplantation (OLT). The overall incidence of HAT in OLT recipients, which was relatively high in the 1980s(4–15%), has dropped to 3–9% in recent literature [1–5]. In a series of 4,234 OLTs, Duffy *et al.* [3]

reported a 5% overall incidence of HAT (3.9% Vs. 8% in adult & paediatric recipients, respectively). According to a systematic review by Bekker *et al.* [4], the incidence of early HAT (e-HAT) 'occurring within the first 30 days post-transplant' ranged from 0% to 6.8% (mean, 2.9%) in adult recipients and from 1% to 20.2% (mean, 8.3%) in paediatric recipients, but there was no statistically significant difference in incidence between living-donor liver transplantation [LDLT: 3.1%; 14 studies] & deceased-donor liver transplantation [DDLT: 4.6%; 57 studies]. Hepatic artery thrombosis is not only a common complication, but a devastating one, being one of the major causes of post-transplant graft failure, morbidity and mortality. The overall mortality rate in patients experiencing post-transplant HAT exceeds 50%, but the mortality following e-HAT is considerably higher (up to 55.6%) than that following late HAT 'occurring >30 days post-transplant' (15–22.6%). Hence, prompt diagnosis & management of HAT are crucial for graft salvage [4–9].

Three different treatment modalities for post-transplant HAT are currently employed: urgent re-transplantation, surgical revascularization, and endovascular therapy. Urgent re-transplantation has been traditionally considered as the mainstay of treatment. However, it is hardly feasible in countries where DDLT is not available, owing to the difficulties of finding suitable living donors in emergency settings [10,11]. Surgical revascularization is an effective therapeutic alternative that has been widely used in HAT patients for graft salvage [10,12]. Over the past years, endovascular procedures [intra-arterial thrombolysis (IAT), percutaneous transluminal angioplasty (PTA) & stent placement] have emerged as an appealing, less invasive alternative, with encouraging results [5,10,12–22].

Currently, in most LDLT centres, when e-HAT occurs in the very early post-transplant period '*the first 48 hours (hrs) post-transplant*' (i.e. in the setting of a fresh arterial anastomosis), surgical revascularization is the preferred therapeutic approach. However, over the past decade, a few reports have described the use of endovascular procedures for treatment of e-HAT in the first 48 hrs post-LDLT, but till now, the use of such procedures at this early stage remains controversial, mainly because of the risk of potentially lethal complications (e.g. bleeding, anastomotic disruption) [4,5,12,15,23–26].

Now, the question is *Is endovascular management of e-HAT feasible, safe and effective in the very early post-LDLT period?* To our knowledge, the published reports on endovascular management of e-HAT in the first 48 hrs

after LDLT are quite limited, the numbers of cases reported in those studies are also limited, and no definite conclusions regarding safety & efficacy of endovascular therapy in the very early post-transplant period have yet been reached. Hence, in view of the scarcity of available data, and to help with the ongoing research in this particular area, we carried out this retrospective cohort study in order to review our 18-year experience with e-HAT following LDLT, as well as to assess the feasibility, efficacy and potential risks of endovascular management of e-HAT in the first 48 hrs post-LDLT.

Patients and methods

Patients

The medical records of 730 patients (recipients) who underwent adult-to-adult LDLT between August 2001 & December 2019 at 3 transplant centres in Egypt (Cairo University Hospitals, Dar Al-Fouad Hospital & El-Sheikh Zayed Specialized Hospital) were retrospectively reviewed. All cases who had developed e-HAT, defined as 'thrombotic hepatic artery (HA) occlusion occurring within the first 30 days post-transplant', were identified & evaluated. Informed consent, including consenting to the use of anonymous data for research purposes, was obtained from all patients prior to LDLT. The study protocol was approved by the Ethical Committees of the aforementioned institutions and conformed to the ethical guidelines of the 2000 Declaration of Helsinki as well as the Declaration of Istanbul 2008.

Hepatic arterial reconstruction & intra-operative imaging in liver transplant recipients

Over the study period, a standardized, comprehensive and regularly updated LDLT protocol was strictly followed. According to this protocol, HA reconstruction in the recipient was undertaken after graft reperfusion (initial antegrade reperfusion via the portal vein) by anastomosing the graft artery to the recipient right, left or middle HA, or to one of the smaller branches of the right HA, in an end-to-end fashion. To ensure proper selection of the most suitable recipient artery for reconstruction, five key factors were carefully considered intra-operatively: vessel size compared to the graft artery (to minimize size mismatch); adequate length (to allow tension-free anastomosis); good quality with preserved intimal integrity; adequate flow; and proper presumed alignment of both the planned arterial and biliary anastomoses. Under 4×–8× loupe

magnification, interrupted 8-0 nonabsorbable, monofilament PROLENE® or ETHIBOND EXCEL® sutures (ETHICON™) were used for reconstruction (Fig. 1). Intra-operative Doppler ultrasound scanning (DUS) was then used to confirm the adequacy of hepatic venous outflow, portal venous flow & hepatic arterial flow, as well as to exclude any related vascular complications. Any graft inflow problems were dealt with accordingly. The normal HA spectral Doppler waveform was defined as 'biphasic waveform with a resistivity index (RI) of 0.55–0.8'. In presence of size mismatch, an anastomotic jet, defined as '2- to 3-fold increase in HA anastomotic flow velocity compared to preanastomotic velocity', was considered normal so long as there was a normal intrahepatic flow pattern. High anastomotic jet (>3-fold), damped intrahepatic peak systolic velocity & increased systolic acceleration time (Tardus-Parvus waveform) were all suggestive of hepatic artery stenosis (HAS).

Postoperative follow-up

Postoperatively, pharmacological thromboprophylaxis was started once the International Normalized Ratio (INR) was <1.5 & the platelet count >50,000/ μ l. This consisted initially of anticoagulant therapy (Enoxaparin 40 mg daily, fondaparinux 5 mg daily or recombinant hirudin 15 mg q12h) that was continued until the patient no longer had significantly reduced mobility but for not less than 2 weeks, followed by antiplatelet therapy (oral aspirin 81 mg daily for 6 months). Serial DUSs were performed 12-hourly for 1 week, then once daily till hospital discharge. If abnormal HA flow [damped flow/abnormal RI (<0.55 or >0.80)] was detected, with no clinical or laboratory findings suggestive of HAT, strict follow-up with DUS was undertaken. However, if two consecutive scans – performed by two different sonographers – revealed absent HA flow, Multi-Detector Computed Tomographic Angiography (MDCTA) or Digital Subtraction

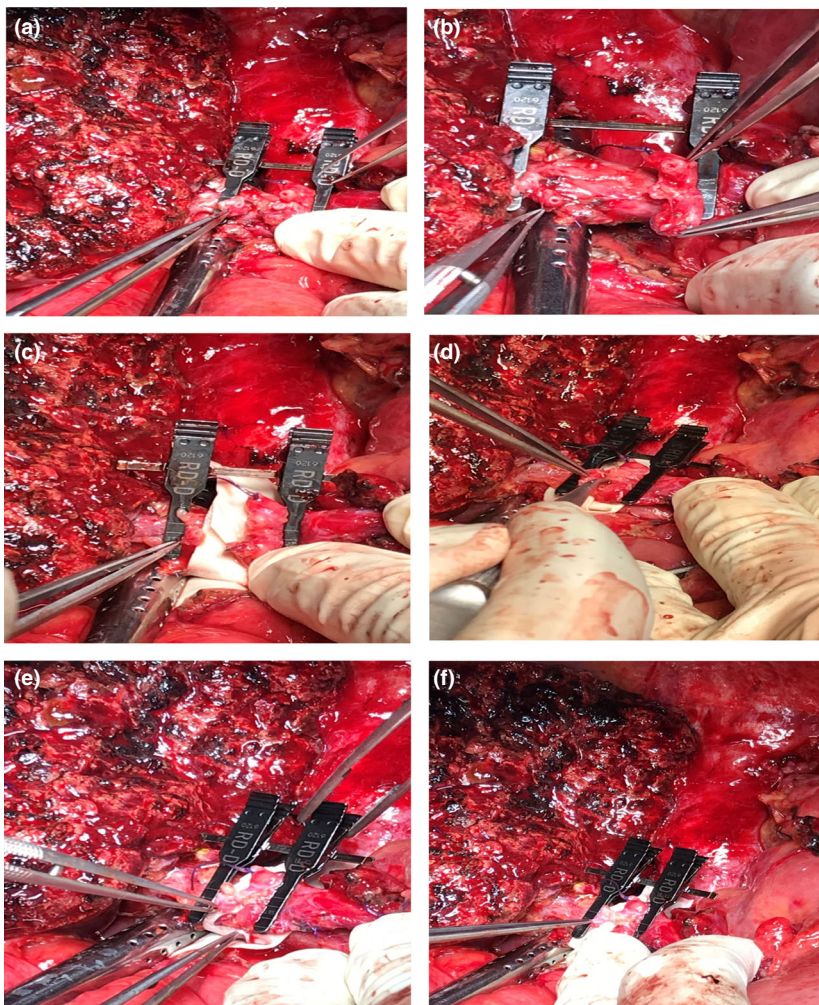


Figure 1 Hepatic arterial reconstruction in one of the liver transplant recipients: (a, b, c) After graft reperfusion, the graft artery and the recipient middle hepatic artery (MHA) were prepared for anastomosis. A microvascular approximator double clamp was applied to both arteries (d, e, f) The graft artery and the recipient MHA were approximated using the double clamp. Arterial reconstruction was then undertaken, in an end-to-end fashion, using interrupted 8-0 nonabsorbable, monofilament sutures

Angiography (DSA) was urgently performed to confirm the diagnosis. Nevertheless, in cases with a very typical picture & a very clear diagnosis of HAT (i.e. acute clinical deterioration, shooting liver enzymes & absent HA flow on two consecutive DUSs performed by two different ultrasound experts), arterial revascularization was urgently carried out without resorting to diagnostic angiography.

Management of early hepatic artery thrombosis (e-HAT)

The management strategies in e-HAT patients 'Target study patients (TSPs)' were highly individualized & were decided on a case-by-case basis through a multidisciplinary team (MDT) approach involving microvascular surgeons, transplant surgeons, interventional radiologists and hepatologists. Surgical revascularization & endovascular therapy were the only feasible therapeutic options. According to our protocol, endovascular therapy was absolutely contraindicated in patients with any of the well-known absolute contraindications to thrombolytic therapy [e.g. acute intracranial haemorrhage (ICH), history of ICH, severe uncontrolled hypertension, active bleeding (excluding menses), significant head trauma or stroke in the previous 3 months] [27]. In addition, hepatic arterial revascularization (surgical/endovascular) was absolutely contraindicated in patients with '*irreversible graft failure requiring urgent re-transplantation*' for whom revascularization would be futile.

If the MDT decision was to proceed with surgical revascularization, urgent relaparotomy & redo HA reconstruction were undertaken. If possible, the graft artery was directly anastomosed to one of the recipient HAs; but if that was not possible (e.g. too short or too small other recipient HAs), alternative arterial inflow options had to be considered [e.g. splenic artery, gastroduodenal artery, autologous bypass graft (such as long saphenous vein or jejunal artery)]. However, if the MDT decision was to proceed with endovascular therapy, conventional diagnostic arteriography was urgently performed. Using the Seldinger technique, selective celiac trunk catheterization was achieved via right femoral artery access using 5-Fr Cobra 2 (C2)/Simmons-2 catheters. Once the diagnosis of HAT was established, a micro-guidewire was carefully introduced into the occluded arterial segment; then, an end-hole microcatheter was advanced over the micro-guidewire into the thrombus. With the microcatheter tip positioned inside the thrombus, IAT was initiated using tissue plasminogen activator (tPA) [3 mg bolus dose, gradually increased (up to 15 mg) till thrombus re-

canalization]. Early in our series, however, when tPA was not yet available, streptokinase (SK) [150,000 IU bolus dose] was used. After re-canalization, angiography was performed. Successful IAT was defined as 'complete or partial thrombus resolution with opacified intrahepatic arterial branches'. If the angiogram following successful thrombolysis revealed underlying HAS (anastomotic/nonanastomotic), the degree of stenosis was assessed using serial angiography. Hepatic arterial stenoses were classified according to the degree of luminal narrowing into mild (<25%), moderate (25–50%) & severe (>50%). In cases with moderate-to-severe stenosis (i.e. $\geq 25\%$ luminal narrowing), PTA and balloon-expandable coronary stent placement were carried out. However, in cases with mild stenosis (i.e. <25% luminal narrowing) and/or residual thrombi, PTA without stenting was undertaken. All interventions were continuously monitored using DUS. If re-canalization did not occur, the procedure was aborted & an urgent MDT decision was made as to whether offer the patient a trial of continuous thrombolytic infusion or to proceed directly with urgent surgical revascularization. If the decision was to proceed with continuous thrombolytic infusion (e.g. in patients who have had a failed surgical revascularization attempt prior to endovascular therapy), the infusion was administered [tPA: the rest of the calculated dose of 0.9 mg/kg – SK:100,000 IU/hour] over a maximum duration of 24 hrs. Meanwhile, hourly DUSs were performed until good arterial flow was confirmed. At this point, thrombolytic infusion was immediately stopped. Initial technical success of a treatment modality was defined as 'complete thrombus resolution without underlying residual stenosis on angiography and with normalization of flow velocities & RI on DUS'.

Follow-up after hepatic arterial revascularization

Postrevascularization, thromboprophylaxis was re-instituted to prevent rebound thrombosis (re-thrombosis) once the INR was <2 & the platelet count >30,000/ μ l. This consisted of anticoagulant therapy [Enoxaparin 1 mg/kg q12h or fondaparinux 7.5 mg daily for 2 weeks, followed by either warfarin or a novel oral anticoagulant for 2 ½ months (e.g. rivaroxaban 15 mg q12h for 2 weeks then 20 mg daily for 2 months)] along with antiplatelet therapy (oral aspirin 81 mg daily for 6 months). Doppler ultrasound scans were performed 12-hourly for 3 days, then daily till hospital discharge. Patients were instructed to come for follow-up weekly for 1 month, then monthly till the 6th month postprocedure, then 3-monthly till the end of the first year,

then 6-monthly thereafter. Definite technical success of a treatment modality (modalities) was defined as 'complete thrombus resolution without underlying residual stenosis or later re-thrombosis'. In case of failure of one of the two feasible treatment modalities (surgical revascularization or endovascular therapy), the other modality was carefully considered.

Data recording

In all TSPs, recipient data [age, gender, Model for End-stage Liver Disease (MELD) score, indication for LDLT]; timing of thrombosis; serum transaminases at diagnosis [stable/mildly-to-moderately elevated/shooting (2- to 3-fold elevation in ≤ 6 hrs)]; treatment modalities employed; treatment outcomes; and complications were all recorded. For analytical purposes, patients were classified into 3 groups: (A): patients who underwent initial surgical revascularization; (B): patients who underwent initial endovascular therapy; and (C): patients who underwent both surgical revascularization & endovascular therapy]. Technical success, procedure-related complications, and 1-year survival rates were determined. Finally, endovascular therapy in the first 48 hrs post-transplant was assessed in terms of feasibility, efficacy, and potential risks.

Statistical analysis

Values were expressed as mean \pm standard deviation or as number (%). Mean values of different variables (numerical data) were compared using Mann–Whitney U test. Categorical variables were compared using chi-square (χ^2) test, or Fisher's exact test whenever appropriate. A P value < 0.05 was considered statistically significant. Data were analysed using *Statistical Package for Social Sciences* (SPSS) software for Windows version 19.

Results

Patient characteristics

Of the 730 patients (recipients) who underwent LDLT over the study period, 31 patients developed e-HAT (4.2%). They ranged in age from 35 to 64 years (mean, 53.1 years), with a male-to-female ratio of 30:1. Indications for LDLT were hepatitis C virus (HCV)-related cirrhosis in 30 cases, 5 of whom were complicated by hepatocellular carcinoma, and autoimmune hepatitis in 1 case. The MELD score at the time of transplant ranged from 11 to 28 (mean, 17.6). All liver grafts used

consisted of right lobe without middle hepatic vein. The timing of development of e-HAT ranged from 1 to 11 days post-transplant (mean, 3.6 days) (Table 1). The diagnosis of HAT was made by DUS in all cases and was confirmed by angiography in 30/31 cases [DSA, $n = 8$ (25.8%); MDCTA, $n = 22$ (71%)]. In only one case, urgent surgical revascularization was carried out on postoperative day (POD)1 without resorting to diagnostic angiography.

Surgical revascularization

Surgical revascularization was carried out in 11 cases (35.5%). Of those, 7 cases (63.6%) underwent initial surgical revascularization [Group A]. The overall definite technical success rate of surgical revascularization was 72.7% (8/11 cases). In 3/11 cases (27.3%), re-thrombosis occurred and endovascular therapy was subsequently carried out for graft salvage.

Endovascular therapy

Endovascular therapy was carried out in 27 cases (87.1%). Of those, 24 cases (88.9%) underwent initial endovascular therapy [Group B]. The overall initial technical success and definite technical success rates of endovascular therapy were 85.2% (23/27 cases) and 70.4% (19/27 cases), respectively. 'Thrombolysis with PTA & stent placement' had a relatively higher definite technical success rate, compared to 'thrombolysis \pm PTA without stenting'; $P = 0.269$, but 1-year survival rates remained comparable in both groups; $P = 0.946$ (Table 2)(Figs 2, 3). In 4/27 cases (14.8%) [failed IAT ($n = 1$); re-thrombosis ($n = 3$)], surgical revascularization was subsequently carried out for graft salvage.

Management of e-HAT in the first 48 hours post-transplant

Fourteen patients (45.2%) developed e-HAT in the first 48 hrs post-transplant. Initial endovascular therapy was carried out in 9/14 cases (64.3%) [29% of TSPs]. All those 9 cases underwent IAT using tPA, and only four of them subsequently underwent PTA & stent placement. The initial technical success, definite technical success and 1-year survival rates of endovascular therapy in the first 48 hrs post-transplant were 88.9% (8/9 cases), 88.9% (8/9 cases) and 55.6% (5/9 cases), respectively, with a 100% definite technical success rate in the 4 cases in whom PTA & stent placement were carried

Table 1. Presentation and management of early hepatic artery thrombosis in the study patients ($n = 31$)

e-HAT	Number of cases (%)
Total number of cases	31/730 (4.2%) <ul style="list-style-type: none"> • Patients with anastomotic HAT ($n = 15$) (i.e. e-HAT occurred on top of an underlying anastomotic problem such as HAS, HAK or size mismatch) • Patients with nonanastomotic HAT ($n = 15$) (i.e. e-HAT occurred without any apparent underlying anastomotic problem). Acute rejection & dehydration have been implicated in some cases • Patients with unidentified type of HAT ($n = 1$)
Timing of thrombosis	1st week: 26/31 (83.9%) 2nd week: 5/31 (16.1%) PODs 1 and 2: 14/31 (45.2%) [8 cases on POD1, 6 cases on POD2]
Serum transaminases (at diagnosis)	Stable: 6/31 (19.3%) Mildly-to-moderately elevated: 11/31 (35.5%) Shooting enzymes: 14/31 (45.2%)
Initial surgical revascularization 'Group A'	7/31 (22.6%) Definite technical success: 4/7 cases (57.1%) Failure: 3/7 cases (42.9%)
Initial endovascular therapy 'Group B'	24/31 (77.4%) Definite technical success: 17/24 cases (70.8%) Failure: 7/24 cases (29.2%)
Both surgical revascularization and endovascular therapy 'Group C'	7/31 (22.6%) <ul style="list-style-type: none"> • Patients who underwent endovascular therapy following failure of surgical management ($n = 3$) • Patients who underwent surgical revascularization following failure of endovascular management ($n = 4$)

e-HAT, early hepatic artery thrombosis; MELD, model for end-stage liver disease; LDLT, living-donor liver transplantation; HCC, hepatocellular carcinoma; POD, postoperative day.

out. On the other hand, surgical revascularization was carried out in the first 48 hrs post-transplant in 6/14 cases (42.9%) [initial surgical revascularization ($n = 5$); surgical revascularization following failure of endovascular management ($n = 1$)], with definite technical success and 1-year survival rates of 83.3% (5/6 cases) & 83.3% (5/6 cases), respectively (Table 3).

Of the 14 patients who developed e-HAT in the first 48 hrs post-transplant, three died of graft failure (Table 3). In 2 of those 3 patients, e-HAT occurred on POD2 & urgent endovascular therapy (IAT using tPA) was carried out. This was technically successful in both cases, but the 2 patients died of graft failure 3 weeks later and 4 weeks later, respectively. Graft failure in both cases was attributed to a combination of irreversible graft ischaemia and biopsy-proven acute rejection. In the third patient, e-HAT occurred on POD1 & urgent surgical revascularization (direct anastomosis) was carried out. Although this was initially successful, re-thrombosis occurred, and endovascular therapy (IAT

using SK) was subsequently carried out for graft salvage. This was also initially successful, but the patient developed re-thrombosis again and died of graft failure 2 weeks later.

Endovascular management of e-HAT after 48 hours post-transplant

In patients who underwent endovascular therapy for e-HAT after 48 hrs post-transplant ($n = 18$) [initial endovascular therapy (15/18 cases), endovascular therapy following failure of surgical management (3/18 cases)], the initial technical success & definite technical success rates of endovascular therapy were 83.3% (15/18 cases) & 61.1% (11/18 cases), respectively, that is endovascular therapy failed in 7/18 cases [procedural technical failure due to arterial dissection ($n = 1$); failed IAT ($n = 2$); re-thrombosis ($n = 4$)] (Tables 2,3). The patient who had procedural technical failure required prolonged ventilatory/circulatory support and died of graft failure 4 weeks

Table 2. Endovascular management of early hepatic artery thrombosis in the study patients ($n = 27$)

Endovascular management of e-HAT	Number of cases (%)
Intra-arterial thrombolysis (IAT)	26/27 (96.3%) In 1/27 cases → the procedure was aborted due to arterial dissection & the patient died of graft failure.
Thrombolytic agent	SK: 9/26 (34.6%) tPA: 17/26 (65.4%)
PTA and stent placement	8/27 (29.6%)
Initial technical success	23/27 (85.2%) -In the first 48 hrs post-transplant: 8/9 cases (88.9%) -After 48 hrs: 15/18 cases (83.3%)
Definite technical success	19/27 (70.4%) IAT ± PTA without stenting: 12/18 cases (66.7%) IAT, PTA & stent placement: 7/8 cases (87.5%)
Failure	8/27 (29.6%) -In the first 48 hrs post-transplant: 1/9 cases (11.1%) -After 48 hrs: 7/18 cases (38.9%) <i>Causes of failure of endovascular therapy (n=8):</i> -Procedural technical failure due to arterial dissection (n=1) -Failed IAT (n=3) Failed IAT using SK (n=2) Failed IAT using tPA (n=1) 'in the first 48 hrs post-LDLT' -Re-thrombosis (n=4) Re-thrombosis after IAT (n=3) Re-thrombosis after IAT, PTA & stent placement (n=1)
Rebound thrombosis	4/27 (14.8%)
Other procedure-related complications	8 complications in 7/27 cases (25.9%) -Post-thrombolysis intraperitoneal bleeding: 4/27 (14.8%) [major in 2 cases]: Successfully managed conservatively -Arterial dissection: 3/27 (11.1%): Successfully managed by stent placement: 2 cases Procedural technical failure: 1 case -Anastomotic rupture: 1/27 (3.7%): Successfully managed by surgical revascularization
One-year survival	16/27 (59.3%) IAT ± PTA without stenting: 11/18 cases (61.1%) IAT, PTA & stent placement: 5/8 cases (62.5%)

e-HAT, early hepatic artery thrombosis; IAT, intra-arterial thrombolysis; PTA, percutaneous transluminal angioplasty; hrs, hours; SK, streptokinase; tPA, tissue plasminogen activator; LDLT, living-donor liver transplantation; re-thrombosis, rebound thrombosis.

postprocedure. Surgical revascularization was avoided in this patient as he was considered to be an 'extremely high-risk candidate with irreversible graft failure'. The 2 patients who had failed IAT died of graft failure 2 weeks later and 2 months later, respectively. Surgical revascularization was also avoided in those 2 patients as it was considered futile in view of the rapid development of graft failure & organ dysfunction in both patients following failure of endovascular management. Unfortunately, urgent re-transplantation – which could have been life-saving in those 2 cases – was not feasible. Of the 4 patients who developed re-thrombosis, three subsequently underwent

surgical revascularization for graft salvage. This was technically successful in the 3 cases, but only 2 patients survived (>1 year), whereas one patient developed portal vein thrombosis & died of graft failure 2 months later. The fourth patient with re-thrombosis had already had a failed attempt at surgical revascularization prior to endovascular therapy. This patient developed re-thrombosis twice, following both initial surgical revascularization & subsequent endovascular therapy. Therefore, of the 7 patients in whom endovascular therapy after 48hrs had failed, only 2 patients were rescued by surgical revascularization.

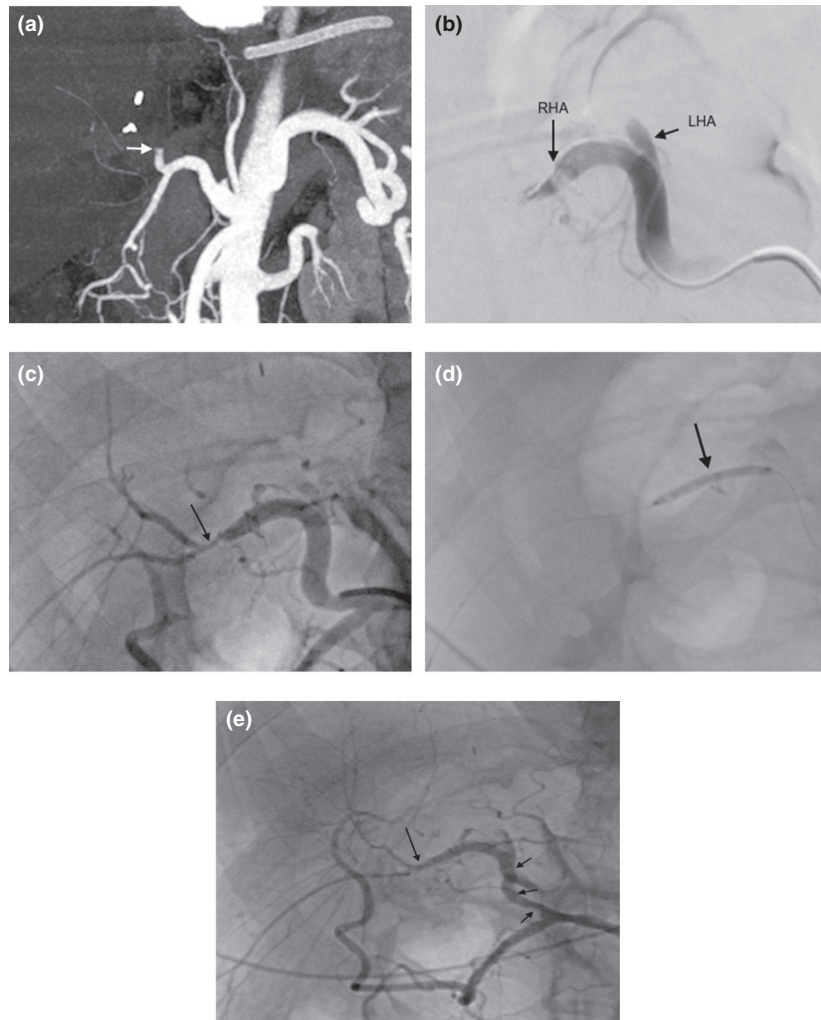


Figure 2 A 57-year-old LDLT recipient with mildly elevated liver enzymes and absent hepatic arterial flow on DUS on day 1 post-transplant: (a) Multi-Detector Computed Tomographic Angiography (MDCTA) image showing occlusion of the CHA (*arrow*). (b) Digital Subtraction Angiography (DSA) image, after super-selective catheterization of the RHA, showing thrombosed RHA (*long arrow*) & ligated LHA stump (*short arrow*). (c) Hepatic angiography image, after a bolus dose of 10mg tPA, showing successful thrombus re-canalization with underlying short segment stricture (*arrow*) and size mismatch between the recipient RHA & the graft artery (4.5mm/1.8 mm). (d) Image taken during balloon dilatation of the stricture up to 2mm. (e) Hepatic angiography image showing good flow in the RHA and across the arterial anastomosis (*long arrow*); note residual spasm in the CHA (*short arrows*). 'LDLT: Living-Donor Liver Transplantation; DUS: Doppler Ultrasound Scanning; CHA: Common Hepatic Artery; RHA: Right Hepatic Artery; LHA: Left Hepatic Artery; tPA: Tissue Plasminogen Activator'

Complications of endovascular therapy

Eight procedure-related complications were reported in 7 out of the 27 cases who underwent endovascular therapy (25.9%). Post-thrombolysis intraperitoneal bleeding was the most common complication [4/27 cases (14.8%), *major bleeding in two cases*]. All the 4 cases with post-thrombolysis bleeding were successfully managed conservatively [maintaining haemodynamic stability/transfusion of blood products (packed red blood cells & fresh frozen plasma)/maintaining haemoglobin concentrations above 7 g%], without the need for

relaparotomy. Among all procedure-related complications, four were reported in 3 out of the 9 cases who underwent endovascular therapy in the first 48 hrs post-transplant (33.3%) [post-thrombolysis intraperitoneal bleeding ($n = 2$, *major bleeding in one case*); arterial dissection ($n = 1$); anastomotic rupture during stent deployment ($n = 1$)] (Tables 2,3).

Overall results of hepatic arterial revascularization

Overall, the definite technical success rate of arterial revascularization [Surgical/Endovascular/Both] was

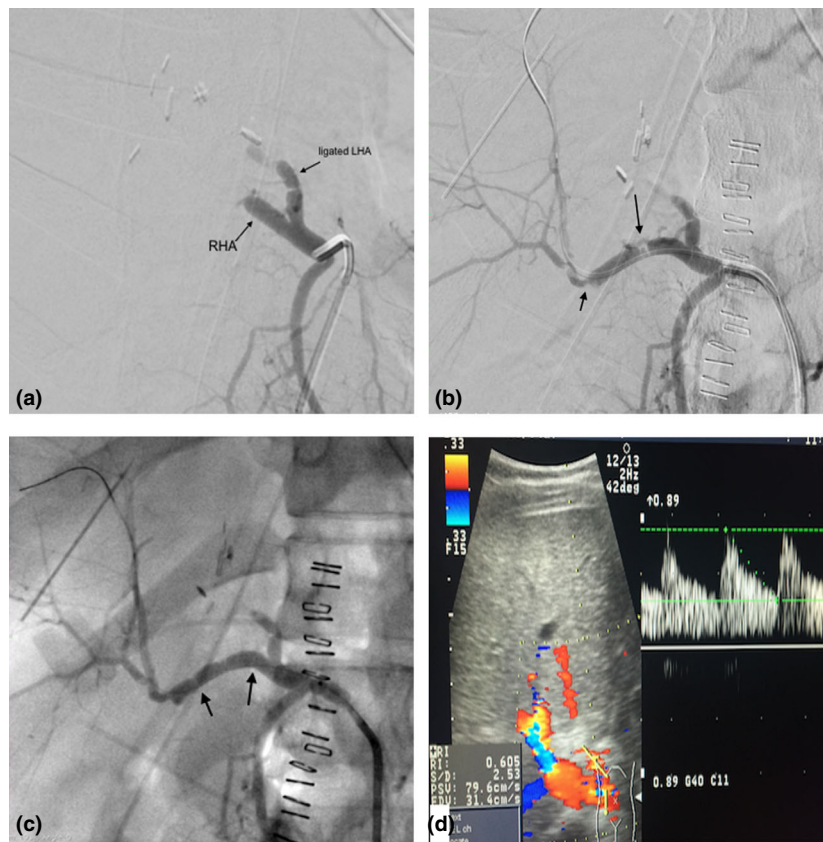


Figure 3 A 35-year-old LDLT recipient with shooting liver enzymes and DUS evidence of hepatic artery thrombosis on day 2 post-transplant: (a) Digital Subtraction Angiography (DSA) image showing thrombosed RHA and ligated LHA stump. (b) Hepatic angiography image, after a bolus dose of 8 mg tPA, showing successful thrombus re-canalization and a significant stricture at the proximal RHA 'probably secondary to clamp injury' (*long arrow*). The arterial anastomosis shows size mismatch between the recipient RHA & the graft artery (4mm/1.9mm), with a mild anastomotic stricture (*short arrow*). (c) Hepatic angiography image after deployment of a 4-mm balloon-expandable stent across the proximal RHA stricture and dilatation of the anastomosis using a 2-mm balloon. (d) Doppler ultrasound image 2 days later showing patent hepatic artery with normal waveform. 'LDLT: Living-Donor Liver Transplantation; DUS: Doppler Ultrasound Scanning; RHA: Right Hepatic Artery; LHA: Left Hepatic Artery; tPA: Tissue Plasminogen Activator'

87.1% (27/31 cases). Re-thrombosis occurred in 6 cases (19.4%). One-year survival rates in patients who underwent surgical revascularization, those who underwent endovascular therapy, and those who underwent both treatment modalities for e-HAT were 72.7% (8/11 cases), 59.3% (16/27 cases) & 57.1% (4/7 cases), respectively. The overall 1-year survival rate in our TSPs was 64.5% (20/31 cases), where 9 patients died of graft failure, one died of severe autoimmune haemolysis and one died of acute myocardial infarction (Table 4).

Discussion

Hepatic artery steno-occlusive disease, the most common arterial complication following LDLT, comprises a spectrum of disorders including HAT, HAS, HAK, arterial steal syndromes and pseudo-aneurysms [28-31]. Of

those, HAT is the most common (~58%) [32]. Risk factors for e-HAT include HAS, HAK, size mismatch, small vessel size, difficult reconstruction, complex anatomy, multiple arterial anastomoses, hypercoagulability and rejection [3,4]. Common presentations include fulminant hepatic failure, acute significant elevation of transaminases, unexplained sepsis & septic shock [33]. Diagnosis is confirmed by DUS and/or angiography, where MDCTA has emerged as a fast, noninvasive imaging modality with 100% sensitivity, 89% specificity & 95% accuracy [34-39].

In order for us to avoid any false results (false-positive or false-negative) regarding a possible HAT diagnosis in any of the transplant patients, our standard practice was to confirm the diagnosis in suspected cases of HAT using urgent MDCTA or DSA. However, in cases with a very typical picture & a very clear diagnosis

Table 3. Clinical features of living-donor liver transplantation, as well as presentation and management of early hepatic artery thrombosis, in three groups of patients in our study: (I) Patients who underwent endovascular therapy in the first 48 hrs post-transplant; (II) Patients who underwent surgical revascularization in the first 48 hrs post-transplant; and (III) Patients who underwent endovascular therapy after 48 hrs post-transplant

Variables	(I)	(II)	(III)	Endovascular management in the first 48 hrs	
	Endovascular management in the first 48 hrs (<i>n</i> = 9) [29% of TSPs]	Surgical management in the first 48 hrs (<i>n</i> = 6) [19.4% of TSPs]	Endovascular management after 48 hrs (<i>n</i> = 18) [58.1% of TSPs]	<i>P</i> value vs. surgical management in first 48 hrs	<i>P</i> value vs. endovascular management after 48 hrs
Recipient factors					
Age (years)	50.89 ± 6.90	50.83 ± 7.44	54.61 ± 5.97	0.635	0.171
Gender (Male : Female)	8:1 (88.9%:11.1%)	6:0 (100%:0%)	18:0 (100%:0%)	0.398	0.15
MELD score (at the time of transplant)	17.11 ± 5.06	18.67 ± 5.13	17.28 ± 4.55	0.408	0.897
Indication for LDLT					
Post-viral cirrhosis (Total)	8 (88.9%)	6 (100%)	18 (100%)	0.398	0.15
<i>Post-viral cirrhosis (no HCC)</i>	6 (66.7%)	6 (100%)	15 (83.3%)	0.287	0.314
<i>Post-viral cirrhosis (HCC)</i>	2 (22.2%)	0 (0%)	3 (17.6%)		
Autoimmune hepatitis	1 (11.1%)	0 (0%)	0 (0%)		
Timing of thrombosis					
POD1	4 (44.4%)	5 (83.3%)	1 (5.6%)	0.132	0.001*
POD2	5 (55.6%)	1 (16.7%)	0 (0.0%)		
After 48 hours	0 (0.0%)	0 (0.0%)	17 (94.4%)		
Degree of elevation of serum transaminases					
No elevation	1 (11.1%)	1 (16.7%)	4 (22.2%)	0.700	0.363
Mild to moderate elevation	5 (55.6%)	2 (33.3%)	5 (27.8%)		
Shooting liver enzymes	3 (33.3%)	3 (50.0%)	9 (50.0%)		
Intra-arterial thrombolysis (IAT)					
No	0 (0.0%)	4 (66.7%)	1 (5.6%)	0.001*	0.019*
Using SK	0 (0.0%)	1 (16.7%)	9 (50.0%)		
Using tPA	9 (100%)	1 (16.7%)	8 (44.4%)		
PTA & stent placement	4 (44.4%)	0 (0.0%)	4 (22.2%)	0.103	0.375
Surgical revascularization					
No	8 (88.9%)	0 (0.0%)	12 (66.7%)	0.001*	0.363
Yes	1 (11.1%)	6 (100%)	6 (33.3%)		
Technique of surgical revascularization					
Direct anastomosis	1 (11.1%)	5 (83.3%)	6 (33.3%)	0.003*	0.214
Anastomosis using LSV graft	0 (0.0%)	1 (16.7%)	0 (0.0%)		
N/A	8 (88.9%)	0 (0.0%)	12 (66.7%)		
Definite technical success rate	8 (88.9%)	5 (83.3%)	11 (61.1%)	0.756	0.136
Rebound thrombosis	0 (0.0%)	1 (16.7%)	5 (27.8%)	0.205	0.080
Procedure-related complications	3 (33.3%)	0 (0.0%)	4 (22.2%)	0.114	0.535
Graft failure	2 (22.2%)	1 (16.7%)	7 (38.9%)	0.792	0.386
Both surgical revascularization and endovascular therapy	1 (11.1%)	2 (33.3%)	6 (33.3%)	0.525	0.363
One-year survival rate	5 (55.6%)	5 (83.3%)	11 (61.1%)	0.580	0.782

TSPs, target study patients; MELD, model for end-stage liver disease; LDLT, living-donor liver transplantation; HCC, hepatocellular carcinoma; POD, postoperative day; SK, streptokinase; tPA, tissue plasminogen activator; PTA, percutaneous transluminal angioplasty; LSV, long saphenous vein; n/a, not applicable; hrs, hours; vs, versus.

**P* < 0.05 = significant

of HAT on clinical, laboratory & two consecutive DUS evaluations, arterial revascularization was urgently carried out without resorting to diagnostic angiography. The rate of e-HAT in this series (4.2%) was comparable to the rates reported in 3 recent LDLT series (1.9%, 2.7%, 3.1%) [8,23,40], as well as to those reported in a systematic review of 21,822 OLTs [mean incidence:3.9%; Europe:3.7%, Asia:3.3%, North America:4.6%, other continents:4.8%] [4]. However, the mean timing of thrombosis [3.6 days (range: 1–11 days post-transplant)] was relatively lower than that reported in the literature [6.9 days (range: 1–17.5 days post-transplant)] [4].

In countries where DDLT is not available & in areas with organ shortage, surgical revascularization and endovascular therapy are the only feasible treatment modalities for e-HAT. Still, however, there are no definite criteria for selecting the most ideal revascularization approach [10,11,23,35]. In this series, the management strategies for e-HAT were decided after careful consideration of a variety of factors, the most important of which was the 'timing of thrombosis'. Other factors included possible underlying causes (e.g. HAS, HAK, size mismatch, vasospasm); technical details of the reconstruction performed; state of other recipient arteries; intra-operative DUS findings; opinion of the surgeon who performed the anastomosis; graft function; patient's general condition; as well as previous surgical/endovascular revascularization attempt(s). In view of this large number of factors that need to be carefully considered prior to making a decision on the most appropriate management strategy for each individual patient, and in order to ensure a very quick, accurate & precise decision-making process in all e-HAT patients, an MDT approach to decision-making was strictly followed in all cases, and the management strategies were decided on a case-by-case basis.

Based on our LDLT protocol, surgical revascularization was the preferred approach for dealing with e-HAT in the very early post-transplant period (i.e. the first 48 hrs post-LDLT), mainly because of the potential hazards of endovascular therapy at this stage (e.g. bleeding, dissection, anastomotic disruption), besides the presumed relative ease of surgery as adhesions had not yet developed. Meanwhile, endovascular therapy was the preferred approach after 48 hrs because of the presumed relative increase in difficulty & risks of surgery at this stage [e.g. injury to vascular pedicle and/or biliary anastomosis, biliary stent(s) dislodgement] [11]. However, with the growing expertise of interventional radiologists over time, endovascular therapy has gradually become a

viable second-line option for dealing with e-HAT in the first 48 hrs post-transplant in certain situations where surgical revascularization was considered futile (e.g. too short graft artery); potentially too complex [e.g. difficult primary arterial reconstruction, too short other recipient HAs (cannot be anastomosed without tension)]; too small other recipient HAs (≤ 1 mm)]; or potentially more risky, compared to endovascular therapy (e.g. significant haemodynamic instability, acute respiratory compromise, acute kidney injury, concomitant major bile leak) (Fig. 4).

In this series, there was no lower limit of vessel diameter for endovascular therapy to be carried out. So, even if the vessel diameter (especially the graft artery) was ≤ 2 mm in a patient with e-HAT & the MDT decision was to proceed with endovascular therapy, IAT was initiated using tPA or SK, and if the angiogram following successful thrombolysis revealed moderate-to-severe stenosis, a 2 mm balloon-expandable coronary stent 'available in our unit' was carefully deployed under nominal pressure.

In our study, the definite technical success, re-thrombolysis & 1-year survival rates of surgical revascularization were 72.7%, 27.3% & 72.7%, respectively, whereas those of endovascular therapy were 70.4%, 14.8% and 59.3%, respectively. Of the 11 TSPs who died, four died of graft failure despite definite technical success of endovascular management, most likely secondary to irreversible graft ischaemia \pm associated acute rejection (Table 4). Post-thrombolysis bleeding was the most common complication of endovascular therapy (14.8%). 'Thrombolysis with PTA & stent placement' was associated with a relatively higher definite technical success rate, compared to 'thrombolysis \pm PTA without stenting'; $P = 0.269$. These findings are somehow consistent with previous literature. In a large systematic review, the success rate of surgical revascularization for e-HAT was 66.1% when daily DUS was performed [4]. In 6 other studies, 12 cases of surgical revascularization in conjunction with IAT were reported with mean re-thrombolysis & graft survival rates of 22% & 65%, respectively [5,33,41-44]. Sixteen other studies described 69 cases of IAT for post-transplant HAT [post-DDLT, $n = 63$ (91.3%); post-LDLT, $n = 6$ (8.7%)], with a 68.1% success rate [3,10,13,15-22,34,45-49]. Haemorrhage was the most common complication in these studies and was fatal in 20% of cases [13,20,46]. Clinical efficacy & safety of IAT have been demonstrated with different thrombolytic dosing regimens [14]. Despite the proven advantages of selective IAT, there is still no consensus on its optimal technique [16-19,50], but Figueras *et al.* [16]

Table 4. Hepatic arterial revascularization 'Surgical/Endovascular/Both' in the study patients ($n = 31$)

Hepatic arterial revascularization	Number of cases (%)
Overall definite technical success	27/31 (87.1%)
Rebound thrombosis	6/31 (19.4%) [Group A (n=3); Group B (n=3)] <i>Timing of re-thrombosis:</i> On day 1 postprocedure (n=2) On day 2 postprocedure (n=3) On days 3 and 1 postprocedure (n=1) One patient in group A developed re-thrombosis twice (following both initial surgical revascularization & subsequent endovascular therapy). Re-thrombosis occurred on day 3 & day 1 postprocedure, respectively.
Overall one-year survival	20/31 (64.5%)
Overall one-year mortality	11/31 (35.5%) 11/31 (35.5%) <ul style="list-style-type: none"> • 7/11 cases (63.6%) died despite definite technical success of arterial revascularization <ul style="list-style-type: none"> - 5 cases: Graft failure Graft failure despite definite technical success of endovascular management (n=4) Portal vein thrombosis & graft failure despite definite technical success of surgical management (n=1) - 1 case: Severe autoimmune haemolysis - 1 case: Acute myocardial infarction • 4/11 cases (36.4%) died of graft failure after failure of arterial revascularization
Late biliary strictures	3/31 (9.7%)

Re-thrombosis, rebound thrombosis.

suggested that continuous infusion would be more effective & safer if the catheter was placed inside the thrombus. Controneo *et al.* [45] reported 18–25 months patency in all patients who underwent stent placement for post-OLT HAS/HAT ($n = 4$).

Currently, in most LDLT centres around the world, surgical revascularization is the preferred therapeutic approach for dealing with e-HAT in the very early post-transplant period '*the first 48 hrs post-transplant*'; but over the past decade, a few reports have described the use of endovascular procedures for treatment of e-HAT at this early stage [4,5,12,15,23–26]. For instance, a recent LDLT report by Choi *et al.* [23] has shown that surgical revascularization was the most commonly employed initial treatment modality in the 7 patients who developed e-HAT in the first postoperative week [4 cases (57.1%)/POD1; $n = 4$ /technical success rate: 100%], whereas endovascular therapy was carried out in the remaining 3 cases (42.9%) [POD1; $n = 2$ /technical success rate: 66.7%], two of whom developed graft failure & underwent re-transplantation. Another LDLT study by Lee *et al.* [24] has described successful endovascular therapy in 8/10 cases of HA occlusion within 24 hrs post-transplant [IAT ($n = 5$); stent placement ($n = 2$); both ($n = 3$)]. Furthermore, in a recent

retrospective review of 756 LDLT procedures by Park *et al.* [26], all the 14 patients who developed e-HAT (1.9%) underwent immediate endovascular therapy, with final success, bleeding and re-thrombosis rates of 71.4% (10/14 cases), 21.4% (3/14 cases) & 28.6% (4/14 cases), respectively. Of note, e-HAT occurred in the first 48 hrs post-transplant in 13 of those patients; and endovascular therapy was successful in 4 out of the 5 cases in whom stent placement was carried out.

In our series, 9 patients underwent endovascular therapy for e-HAT in the first 48 hrs post-transplant (29% of TSPs), with definite technical success & 1-year survival rates of 88.9% & 55.6%, respectively. Stent placement during this very early post-transplant period (i.e. *early stenting*) was associated with a 100% definite technical success rate. When the group of patients who underwent endovascular therapy for e-HAT in the first 48 hrs post-transplant ($n = 9$) was compared to those who underwent endovascular therapy after 48 hrs ($n = 18$), there was no statistically significant difference between the 2 groups in terms of definite technical success, re-thrombosis, procedure-related complications, graft failure and 1-year survival rates ($P = 0.136, 0.080, 0.535, 0.386$ & 0.782 , respectively). However, it is worth pointing out that the definite technical success rate of

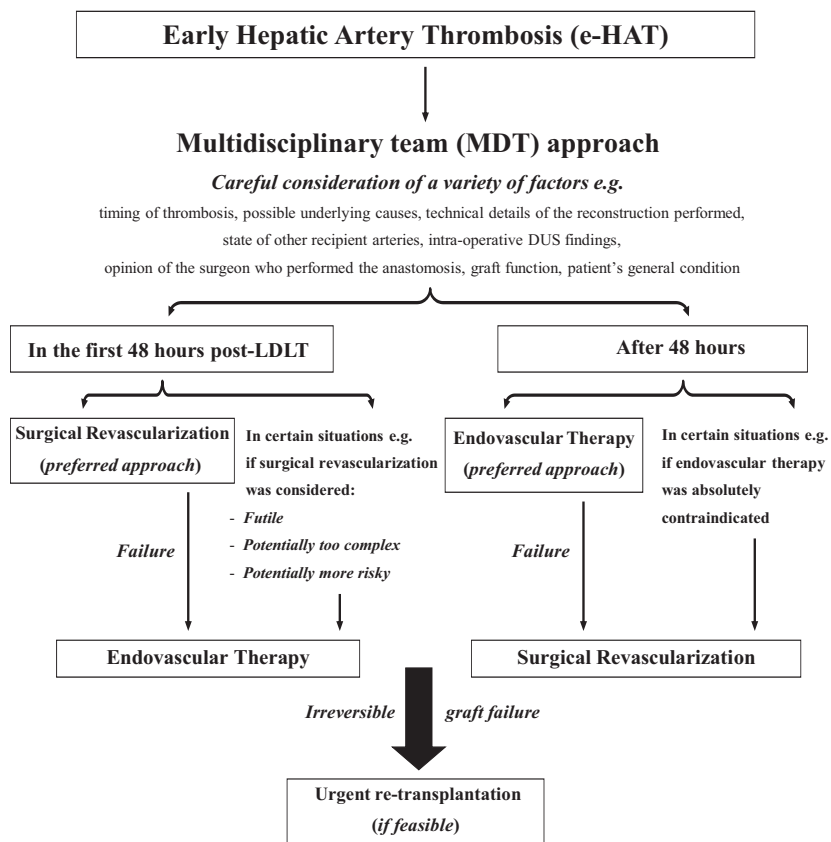


Figure 4 Algorithm for treatment of early hepatic artery thrombosis (e-HAT) in LDLT recipients [Note: Urgent re-transplantation was not feasible at the transplant centres where the study was conducted]. ‘LDLT: Living-Donor Liver Transplantation; DUS: Doppler Ultrasound Scanning’

endovascular therapy after 48 hrs was relatively low compared to that of endovascular therapy in the first 48 hrs post-transplant (61.1% vs. 88.9%, respectively) in spite of the almost equivalent initial technical success rates in the aforementioned groups (83.3% vs. 88.9%, respectively). This was mainly attributed to the relatively higher rate of re-thrombosis following endovascular therapy after 48 hrs. Moreover, when the group of patients who underwent surgical revascularization in the first 48 hrs post-transplant ($n = 6$) was compared to those who underwent endovascular therapy within the same time frame ($n = 9$), there was no statistically significant difference between the 2 groups in terms of the aforementioned rates ($P = 0.756, 0.205, 0.114, 0.792$ & 0.580 , respectively) (Tables 2,3). All the above-mentioned findings largely support the feasibility & efficacy of endovascular management of e-HAT in the first 48 hrs after LDLT, including stent placement ‘early stenting’. Nevertheless, the incidence of procedure-related complications, especially post-thrombolysis bleeding, was relatively higher in patients who underwent endovascular therapy in the first 48 hrs post-transplant [33.3% (3/9 cases)] compared to those who underwent surgical revascularization [0.0% (0/6 cases)]; $P = 0.114$. This noteworthy finding draws attention to the critical

importance of carefully considering the potential risks of endovascular therapy before selecting this management approach in e-HAT patients in the first 48 hrs post-transplant, as well as taking the utmost technical precautions possible if endovascular therapy was to be carried out during this period. Our findings are consistent with Lee *et al.* [24] who reported successful endovascular therapy in 8/10 cases of HA occlusion within 24 hrs post-LDLT, where anastomotic-site bleeding occurred in 2/10 cases, prompting re-transplantation. The authors suggested that endovascular therapy could be an alternative therapeutic option for HA occlusion in the first 24 hrs post-transplant. Our findings also agree with Park *et al.* [26] who reported successful endovascular therapy in 10/13 cases of e-HAT in the first 48hrs post-LDLT, where bleeding occurred in 2/13 cases, prompting endovascular embolization in one patient & laparotomy in the other.

Finally, it is worth pointing out that in our LDLT experience, with time, we gradually implemented some additional technical precautions, aiming to minimize the potential risks of endovascular therapy as much as possible. First, to minimize the risk of post-thrombolysis bleeding, we used to slowly administer the 3 mg tPA bolus dose and to gradually increase the dosage as

needed (up to a maximum dose of 15 mg) using slow intermittent injections under the continuous guidance of control angiography till thrombus re-canalization. In addition, we totally avoided the use of continuous thrombolytic infusion in patients with unsuccessful endovascular re-canalization in the first 48 hrs post-transplant, and we proceeded directly to urgent surgical revascularization in those patients. Second, we noticed that arterial dissection/vasospasm occurred when the diagnostic or guiding catheters were advanced beyond the celiac trunk into the common HA or the proper HA which were usually diseased (atherosclerotic), besides being quite friable in the early post-transplant period. So, to minimize the risk of arterial dissection/vasospasm, we used to fix those catheters in the celiac trunk, then introduce the micro-guidewire & the microcatheter into the common HA. Third, we avoided the use of oversized balloons/stents in order to minimize the risk of anastomotic rupture.

Limitations of this retrospective study included the relatively small sample size & the presence of various factors, other than e-HAT, that influenced survival rates in the TSPs.

Conclusions

Early hepatic artery thrombosis following LDLT can be treated by surgical revascularization or endovascular therapy, with comparable technical success and 1-year survival rates. Post-thrombolysis bleeding is the most common complication of endovascular therapy. Endovascular management of e-HAT in the first 48 hours post-LDLT, including stent placement ‘*early stenting*’, appears to be a feasible and effective therapeutic option. However, it is associated with a relatively higher risk of procedure-related complications, compared to surgical revascularization. Hence, it can be reserved as a second-line option for treatment of e-HAT in the first 48 hours post-transplant in certain situations where surgical revascularization is considered futile, potentially too complex or potentially more risky.

Further studies with larger sample sizes are still needed in order to reach definite conclusions regarding the safety of endovascular therapy in the very early post-transplant period.

Authorship

O. A.: Designed research/study, performed research/study, collected data. A. M. A. O.: Designed research/study, performed research/study, analyzed data, wrote the paper. K. A. H.: Designed research/study, performed research/study. S. E.: Performed research/study. D. K. S.: Performed research/study. M. M.: Performed research/study, supervised research/study. All authors: Approved the article.

Funding

None.

Conflict of interest

The authors declare that they have no conflicts of interest to disclose.

Acknowledgements

None.

Ethical statement

All human studies have been reviewed by the appropriate ethics committee and have therefore been performed in accordance with the ethical standards laid down in an appropriate version of the 2000 Declaration of Helsinki as well as the Declaration of Istanbul 2008.

Informed Consent

All individual participants gave their informed consent prior to their inclusion in the study.

REFERENCES

1. Tzakis AG, Gordon RD, Shaw BW Jr, Iwatsuki S, Starzl TE. Clinical presentation of hepatic artery thrombosis after liver transplantation in the cyclosporine era. *Transplantation* 1985; **40**: 667.
2. Scarinci A, Sainz-Barriga M, Berrevoet F, et al. Early arterial revascularization after hepatic artery thrombosis may avoid graft loss and improve outcomes in adult liver transplantation. *Transplant Proc* 2010; **42**: 4403.
3. Duffy JP, Hong JC, Farmer DG, et al. Vascular complications of orthotopic liver transplantation: experience in more than 4,200 patients. *J Am Coll Surg* 2009; **208**: 896.
4. Bekker JS, Ploem S, de Jong KP. Early hepatic artery thrombosis after liver transplantation: a systematic review of the incidence, outcome, and risk factors. *Am J Transpl* 2009; **9**: 746.

5. Stange BJ, Glanemann M, Nuessler NC, Settmacher U, Steinmüller T, Neuhaus P. Hepatic artery thrombosis after adult liver transplantation. *Liver Transpl* 2003; **9**: 612.
6. Bhattacharjya S, Gunson BK, Mirza DF, et al. Delayed hepatic artery thrombosis in adult orthotopic liver transplantation - a 12-year experience. *Transplantation* 2001; **71**: 1592.
7. Wu L, Zhang J, Guo Z, et al. Hepatic artery thrombosis after orthotopic liver transplant: a review of the same institute 5 years later. *Exp Clin Transplant* 2011; **9**: 191.
8. Steinbrück K, Enne M, Fernandes R, et al. Vascular Complications After Living Donor Liver Transplantation: A Brazilian, Single-Center Experience. *Transplant Proc* 2011; **43**: 196.
9. Ashok T, Long-Bin J, Shih-Chao H, et al. Management of Hepatic Artery Thrombosis after Living Donor Liver Transplantation: Endovascular Thrombolytic Therapy or Surgical Intervention? Role of Hepatic Arterial Urokinase Infusion. *Surg Gastroenterol Oncol* 2018; **23**: 159.
10. Singhal A, Stokes K, Sebastian A, Wright HI, Kohli V. Endovascular treatment of hepatic artery thrombosis following liver transplantation. *Transpl Int* 2010; **23**: 245.
11. Abdelaziz O, Hosny K, Amin A, Emadeldin S, Uemoto S, Mostafa M. Endovascular management of early hepatic artery thrombosis after living donor liver transplantation. *Transpl Int* 2012; **25**: 847.
12. Langnas AN, Marujo W, Stratta RJ, Wood RP, Shaw BW Jr. Vascular complications after orthotopic liver transplantation. *Am J Surg* 1991; **161**: 76.
13. Saad WEA, Davies MG, Saad NEA, et al. Catheter thrombolysis of thrombosed hepatic arteries in liver transplant recipients: predictors of success and role of thrombolysis. *Vasc Endovasc Surg* 2007; **41**: 19.
14. Boyvat F, Aytakin C, Firat A, Harman A, Karakayali H, Haberal M. Diagnostic and therapeutic management of hepatic artery thrombosis and stenosis after orthotopic and heterotopic liver transplantation. *Transplant Proc* 2003; **35**: 2791.
15. Hidalgo EG, Abad J, Cantarero JM, et al. High-dose intra-arterial urokinase for the treatment of hepatic artery thrombosis in liver transplantation. *Hepatogastroenterology* 1989; **36**: 529.
16. Figueras J, Busquets J, Dominguez J, et al. Intraarterial thrombolysis in the treatment of acute hepatic artery thrombosis after liver transplantation. *Transplantation* 1995; **59**: 1356.
17. Zhou J, Fan J, Wang JH, et al. Continuous transcatheter arterial thrombolysis for early hepatic artery thrombosis after liver transplantation. *Transplant Proc* 2005; **37**: 4426.
18. Kim BW, Won JH, Lee BM, Ko BH, Wang HJ, Kim MW. Intraarterial thrombolytic treatment for hepatic artery thrombosis immediately after living donor liver transplantation. *Transplant Proc* 2006; **38**: 3128.
19. Li ZW, Wang MQ, Zhou NX, Liu Z, Huang ZQ. Interventional treatment of acute hepatic artery occlusion after liver transplantation. *Hepatobiliary Pancreat Dis Int* 2007; **6**: 474.
20. Yang Y, Li H, Fu BS, et al. Hepatic artery complications after orthotopic liver transplantation: interventional treatment or retransplantation? *Chin Med J* 2008; **12**: 1997.
21. Lopez BR, Schlieter M, Hallscheidt PJ, et al. Successful arterial thrombolysis and percutaneous transluminal angioplasty for early hepatic artery thrombosis after split transplantation in a 4-month-old baby. *Pediatr Transpl* 2008; **12**: 606.
22. Boyvat F, Aytakin C, Harman A, Sevmiş S, Karakayali H, Haberal M. Endovascular stent placements in patients with hepatic artery stenosis or thrombosis after liver transplantation. *Transplant Proc* 2008; **40**: 22.
23. Choi HJ, Kim DG, Kim Y, et al. Clinical Course of Hepatic Artery Thrombosis After Living Donor Liver Transplantation Using the Right Lobe. *Liver Transpl* 2018; **24**: 1554.
24. Lee IJ, Kim SH, Lee SD, Lee JH, Kim HB. Feasibility and Midterm Results of Endovascular Treatment of Hepatic Artery Occlusion within 24 Hours after Living-Donor Liver Transplantation. *J Vasc Interv Radiol* 2017; **28**: 269.
25. Mourad MM, Lioussis C, Gunson BK, et al. Etiology and management of hepatic artery thrombosis after adult liver transplantation. *Liver Transpl* 2014; **20**: 713.
26. Park J, Kim SH, Park SJ. Hepatic artery thrombosis following living donor liver transplantation: A 14-year experience at a single center. *J Hepatobiliary Pancreat Sci* 2020; **27**: 548.
27. Fugate JE, Rabinstein AA. Absolute and Relative Contraindications to IV rt-PA for Acute Ischemic Stroke. *Neurohospitalist* 2015; **5**: 110.
28. Cavallari A, Vivarelli M, Bellusci R, Jovine E, Mazziotti A, Rossi C. Treatment of vascular complications following liver transplantation: multidisciplinary approach. *Hepatogastroenterology* 2001; **48**: 179.
29. Sanchez-Bueno F, Robles R, Ramirez P, et al. Hepatic artery complications after liver transplantation. *Clin Transplant* 1994; **8**: 399.
30. Stange B, Settmacher U, Glanemann M, Nuessler NC, Bechstein WO, Neuhaus P. Aneurysms of the hepatic artery after liver transplantation. *Transplant Proc* 2000; **32**: 533.
31. Nüssler N, Settmacher U, Haase R, Stange B, Heise M, Neuhaus P. Diagnosis and treatment of arterial steal syndromes in liver transplant recipients. *Liver Transpl* 2003; **9**: 596.
32. Jain A, Costa G, Marsh W, et al. Thrombotic and nonthrombotic hepatic artery complications in adults and children following primary liver transplantation with long-term follow-up in 1000 consecutive patients. *Transpl Int* 2006; **19**: 27.
33. Drazan K, Shaked A, Olthoff KM, et al. Etiology and management of symptomatic adult hepatic artery thrombosis after orthotopic liver transplantation (OLT). *Am Surg* 1996; **62**: 237.
34. Wang XH, Yan LN, Zhang F, et al. Early experiences on living donor liver transplantation in China: multicenter report. *Chin Med J* 2006; **119**: 1003.
35. Hsiao CY, Ho CM, Wu YM, Ho MC, Hu RH, Lee PH. Management of early hepatic artery occlusion after liver transplantation with failed rescue. *World J Gastroenterol* 2015; **21**: 12729.
36. Vignali C, Bargellini I, Cioni R, et al. Diagnosis and treatment of hepatic artery stenosis after orthotopic liver transplantation. *Transplant Proc* 2004; **36**: 2771.
37. Kayahan EM, Coskun M, Ozbek O, et al. Accuracy of multidetector computed tomographic angiography for detecting hepatic artery complications after liver transplantation. *Transplant Proc* 2007; **39**: 3239.
38. Saba L, Mallarini G. Multidetector row CT angiography in the evaluation of the hepatic artery and its anatomical variants. *Clin Radiol* 2008; **63**: 312.
39. Brancatelli G, Katyal S, Federle MP, Fontes P. Three dimensional multislice helical computed tomography with the volume rendering technique in the detection of vascular complications after liver transplantation. *Transplantation* 2002; **73**: 237.
40. Agrawal P, Mohanka R, Rastogi A, et al. Early Hepatic Artery Thrombosis (eHAT) After Living Donor Liver Transplantation: Not So Fatal Anymore!. *J Clin Exp Hepatol* 2014; **4**: S80.
41. Langnas AN, Marujo WC, Wood RP, Stratta RJ, Shaw BW. Hepatic allograft

- rescue following arterial thrombosis: role of urgent revascularization. *Transplantation* 1991; **51**: 86.
42. Inomoto T, Nishizawa F, Sasaki H, *et al.* Experiences of 120 microsurgical reconstructions of hepatic artery in living related liver transplantation. *Surgery* 1996; **119**: 20.
 43. Zheng SS, Yu ZY, Liang TB, *et al.* Prevention and treatment of hepatic artery thrombosis after liver transplantation. *Hepatobiliary Pancreat Dis Int* 2004; **3**: 21.
 44. Garcia-Gallont R, Bar-Nathan N, Shahrabani E, *et al.* Hepatic artery thrombosis in pediatric liver transplantation: graft salvage after thrombectomy. *Pediatr Transplant* 1999; **3**: 74.
 45. Cotroneo AR, DiStasi C, Cina A, *et al.* Stent placement in four patients with hepatic artery stenosis or thrombosis after liver transplantation. *J Vasc Interv Radiol.* 2002; **13**: 619.
 46. Zajko AB, Brom KM, Starzl TE, *et al.* Angiography of liver transplantation patients. *Radiology* 1985; **157**: 305.
 47. Bjerkvik S, Vatne K, Mathisen O, Sor-eide O. Percutaneous revascularization of postoperative hepatic artery thrombosis in a liver transplant. *Transplantation* 1995; **59**: 1746.
 48. Jeon GS, Won JH, Wang HJ, Kim BW, Lee BM. Endovascular treatment of acute arterial complications after living donor liver transplantation. *Clin Radiol* 2008; **63**: 1099.
 49. Reyes-Corona J, Gonzalez-Huezo MS, Zea-Medina MV, Zamora-Valdés D, Victoria-Campos JL, Mondragon-Sanchez RJ. Paclitaxel coated-stent for early onset thrombosis after liver transplantation. *Ann Hepatol* 2007; **6**: 272.
 50. Semba CP, Bakal CW, Calis KA, *et al.* Alteplase as an alternative to urokinase. Advisory Panel on Catheter-Directed Thrombolytic Therapy. *J Vasc Interv Radiol* 2000; **11**: 279.