



ORIGINAL ARTICLE

Clinical implementation of coronary computed tomography angiography for routine detection of cardiac allograft vasculopathy in heart transplant patients

Fay M. A. Nous^{1,2}, Stefan Roest^{2,3} , Eva D. van Dijkman^{1,2}, Mohamed Attrach¹, Kadir Caliskan^{2,3}, Jasper J. Brugts^{2,3}, Koen Nieman^{1,2,4}, Alexander Hirsch^{1,2}, Alina A. Constantinescu^{2,3}, Olivier C. Manintveld^{2,3,*} & Ricardo P.J. Budde^{1,2,*} 

1 Department of Radiology and Nuclear Medicine, Erasmus MC, University Medical Center Rotterdam, Rotterdam, the Netherlands

2 Department of Cardiology, Thorax Center, Erasmus MC, University Medical Center Rotterdam, Rotterdam, the Netherlands

3 Erasmus MC Transplant Institute, Erasmus MC, University Medical Center Rotterdam, Rotterdam, the Netherlands

4 Cardiovascular Institute, Stanford University School of Medicine, Stanford, CA, USA

Correspondence

Ricardo P. J. Budde, Erasmus MC, room: Nd-547, Postbus 2040, 3000 CA, Rotterdam, the Netherlands.
Tel: +31 10 704 20 06;
fax: +31 10 703 40 33;
Email: r.budde@erasmusmc.nl

*Authors contributed equally to this work.

SUMMARY

Cardiac allograft vasculopathy (CAV) is an accelerated form of coronary artery disease that affects long-term outcomes in heart transplant (HTx) patients. We prospectively evaluated the feasibility of coronary computed tomography angiography (CCTA) for the detection of CAV during clinical implementation at our center. All consecutive HTx patients >4 years post-transplant were actively converted from myocardial perfusion imaging to CCTA for the annual assessment of CAV. Between February 2018 and May 2019, 129/172 (75%) HTx patients underwent a CCTA. Renal impairment ($n = 21/43$) was the most frequent reason for patients could not undergo CCTA. CCTA image quality was good–excellent in 118/129 (92%) patients, and the radiation dose was 2.1 (1.6–2.8) mSv. CCTA showed obstructive CAV in 19/129 (15%) patients. Thirteen (10%) patients underwent additional tests, of which 8 patients underwent coronary revascularization within 90 days of CCTA. After 1 year, 3 additional coronary angiograms were performed, resulting in one revascularization in a patient with known severe CAV who developed ventricular tachycardia. One myocardial infarction after coronary stenting and 2 non-cardiac deaths were observed. CCTA can be successfully implemented for routine detection of CAV with good image quality and low radiation dose. CCTA allows CAV evaluation with the limited need for additional invasive testing.

Transplant International 2021; 34: 1886–1894

Key words

cardiac allograft vasculopathy, computed tomography angiography, coronary artery disease, heart transplantation, invasive coronary angiography

Received: 29 March 2021; Revision requested: 4 July 2021; Accepted: 8 July 2021

Introduction

Cardiac allograft vasculopathy (CAV) is a major challenge for successful long-term outcomes in heart transplant (HTx) patients and accounts for 1 in 8 deaths

after the first year post-transplantation [1]. CAV is characterized by diffuse coronary wall thickening which progresses to obstructive coronary lesions and consequently leads to ischemic events, heart failure, arrhythmias, and sudden cardiac death [2]. Routine

surveillance of coronary arteries by invasive coronary angiography (ICA) is recommended due to the often silent progression of CAV in denervated transplanted hearts [3]. However, ICA is uncomfortable due to its invasive nature with accompanying procedural risk for complications [4]. Therefore, noninvasive imaging modalities such as coronary computed tomography angiography (CCTA) have been proposed as alternatives. CCTA visualizes both the coronary lumen and wall with high sensitivity (86% to 89%) and specificity (89% to 99%), but has not yet been widely adopted due to concerns about potential lower image quality and higher radiation dose associated with the relatively high heart rates often encountered in HTx patients [5]. However, technical advances including increased detector-row coverage, decreased rotation time, and iterative reconstruction algorithms have improved the image quality of CCTA in patients with elevated heart rates [6,7]. Therefore, CCTA has become a more attractive alternative to ICA for the detection of CAV with more ease for the patient and logistics at a lower cost and could be used as gatekeeper to ICA. This has prompted us to implement routine CCTA for the annual detection of CAV in HTx patients at our center. In the present article, we describe our experience during the first 15 months of implementation in clinical practice and evaluate the feasibility of CCTA as the first-line test for CAV detection.

Materials and methods

Study population

This prospective observational study assessed the clinical implementation of CCTA for the routine detection of CAV in HTx patients at the Erasmus Medical Center over a 15-month period between February 15, 2018 and May 15, 2019. Routine surveillance of CAV at our center was previously performed by ICA in the first and fourth year after HTx and annually by myocardial perfusion imaging (MPI) by single photon emission computed tomography (SPECT), followed by an ICA if myocardial ischemia was present, after the fourth year post-transplantation. All HTx patients are seen at the outpatient clinic in our hospital at least twice a year. Each visit includes a detailed clinical history, extensive blood laboratory tests, medication review, and an imaging test for CAV once every year. Extensive and structured clinical letters of each clinical visit are stored in the electronic medical record of each patient. All consecutive HTx patients who were at least four years post-

transplantation and scheduled for annual routine follow-up at our center were actively converted from undergoing SPECT MPI to CCTA as the first-line test for CAV detection if logistically feasible. Exclusion criteria to convert to CCTA were renal failure (glomerular filtration rate <45 ml/min/1.73 m² prior to March 15, 2018 and <30 ml/min/1.73 m² after March 15, 2018 as our institutional protocol for prevention of contrast nephropathy was changed) or known allergy for iodinated contrast agents. For the purpose of this study, clinical characteristics including patient demographics, CAV scores, and medication use were obtained from local registries and medical records of the most recent outpatient visit. Consequently, none of the HTx patients was included twice. This study was conducted in accordance with the Declaration of Helsinki and approved by the local Ethical Committee of the Erasmus Medical Center (MEC-2017-421).

Cardiac computed tomography

All scans were performed on second- or third-generation dual-source CT scanners (Somatom Definition Drive or Force, Siemens Healthineers). A non-contrast-enhanced scan was performed to calculate the coronary calcium score according to the Agatston method [8]. CCTA examinations were performed following normal clinical routine for CCTA [9]. Patients received sublingual nitroglycerin before CCTA and if indicated (heart rate ≥ 70 /min) intravenous beta-blockers up to the dose approved by the transplant cardiologist that requested the CCTA. A prospective electrocardiographically triggered scan mode was used, with an exposure window during diastole and/or systole depending on the heart rate. Tube current and tube voltage were selected semi-automatically based on body size. A test bolus acquisition was performed using 10–15 ml of contrast medium (Iopromide 37 mg/ml, Bayer, Germany), followed by a 20-ml saline chaser. For the CCTA, a contrast bolus of 50–70 ml was used, followed by a 25-ml saline chaser. Images were reconstructed with a medium smooth kernel, slice thickness of 0.6 mm, and an increment of 0.3 mm. The CCTA scans were assessed by an experienced cardiovascular radiologist with extensive (>10 years) experience in cardiac imaging and reported according to a standardized protocol. The standardized protocol included the following items: (1) CCTA image quality according to a 4-point Likert scale: 1 non-diagnostic; 2 moderate image quality, differentiation of coronary artery wall possible with reduced confidence; 3 good image quality, minimal

artifacts without limiting coronary artery wall differentiation; 4 excellent image quality, no artifacts present and clear differentiation of the coronary artery wall; (2) stenosis grading per vessel, including those with coronary stents: no stenosis, stenosis <50%, stenosis ≥50%; (3) assessment of incidental findings on a large field of view reconstruction that included all the lungs and the chest wall. CCTA-based CAV score was determined based on the International Society for Heart and Lung Transplantation CAV grading scale for ICA where the stenosis threshold was defined as ≥50% stenosis instead of 70% in accordance to the guidelines of the Society of Cardiac Computed Tomography.

Clinical outcomes

Clinical outcomes through 90 days and 1-year post-CCTA were collected including performance of additional tests for coronary ischemia, medication use, coronary revascularization, and the occurrence of major adverse cardiac events defined as cardiac and non-cardiac death, nonfatal myocardial infarction, and unstable angina requiring revascularization. In general, patients with a stenosis >50% on CCTA or with new symptoms suspect for coronary ischemia were considered for additional coronary tests. To determine the impact of CCTA findings on the prescribed medication, the treating clinical physician indicated whether a medication change was initiated based on the CCTA findings.

Statistical analysis

Data are presented as mean ± standard deviation, median with 25th–75th percentile, and totals with percentages where appropriate. A 2-sided p-value of <0.05 was considered statistically significant. Statistical analyses were performed using SPSS (version 25, IBM Corp).

Results

Study population

A total of 129 out of 172 (75%) HTx patients scheduled for noninvasive imaging for the detection of CAV underwent a CCTA (Fig. 1). Renal impairment was the most frequent reason why patients could not undergo CCTA (21 out of 43 (49%) patients), followed by known iodine contrast allergy (9 out of 43 (21%) patients). In 7 out of 172 (4%) patients, the new recommendations were not followed, including 6 patients who did not receive a CCTA because of the clinical preference of the physician to perform a SPECT MPI in patients with known severe CAV (*n* = 5) or angina symptoms (*n* = 1) and one patient who was on hemodialysis without residual diuresis who did receive a CCTA for logistical reasons. Patients who underwent a CCTA were 55 (43–64) years, 11 (8–17) years post-transplantation, 65% were male, and 13% had prior percutaneous coronary interventions (Table 1). One hundred and eleven out of 129 (86%) patients used

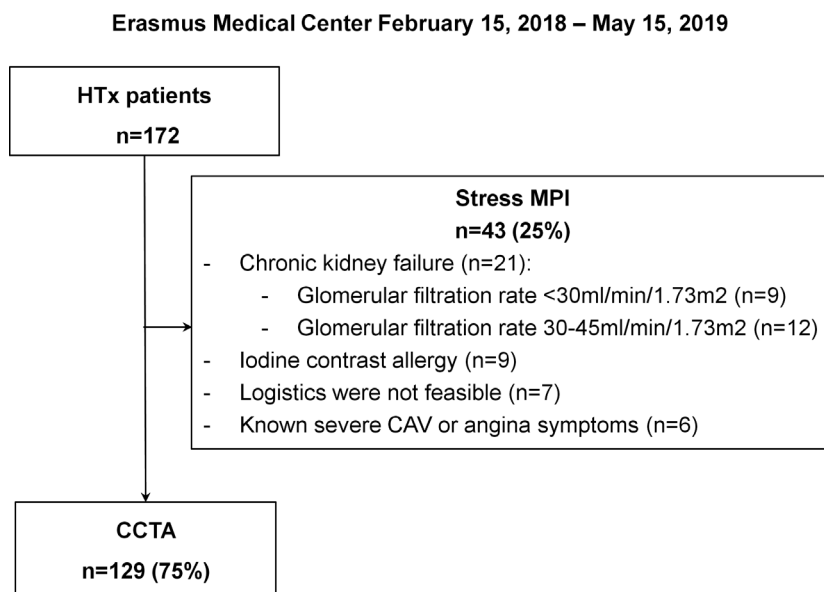


Figure 1 Flowchart of all HTx patients scheduled for annual routine follow-up. CCTA: coronary computed tomography angiography; HTx: heart transplantation; MPI: myocardial perfusion imaging.

Table 1. Baseline patient characteristics.

Total number of patients, <i>n</i>	129
Age, years	55 (43–64)
Recipient gender, % male	84 (65%)
Reason for transplantation	
Ischemic heart disease	36 (28%)
Other	93 (72%)
Time since heart transplantation, years	11 (8–17)
Recipient age at transplant, years	43 (28–52)
Diabetes mellitus recipient prior heart transplant	8 (6%)
Donor age, years	39 (23–49)
Donor gender, % male	56 (43%)
Active cytomegalovirus within first year post-transplant	26 (20%)
Total cellular-mediated rejection periods per patient	1 (0–2)
Total antibody-mediated rejections periods per patient	0 (0–0)
Body mass index, kg/m ²	27 (24–29)
Diabetes mellitus	41 (32%)
Insulin use	14 (11%)
Hypertension	103 (80%)
Smoking	
Current	3 (2%)
Previous	42 (33%)
Never	84 (65%)
Prior percutaneous coronary interventions	17 (13%)
Blood creatinine, μmol/l	107 (88–130)
Glomerular filtration rate CKD-EPI, ml/min/1.73m ²	62 (48–79)
Left ventricular ejection fraction <50%	5 (4%)
Statin and/or Ezetimibe use	111 (86%)
Thrombocyte aggregation inhibitors and/or oral coagulant use	121 (94%)
Current immunosuppressive regimen	
Calcineurin inhibitors	129 (100%)
Steroids	88 (68%)
Mycophenolate mofetil	48 (37%)
Mammalian target of rapamycin receptor inhibitors	27 (21%)
Purine antagonists	3 (2%)

Continuous data are presented as median with 25th–75th percentiles and categorical data as number of patients with percentages. CCTA: coronary computed tomography angiography.

statins and/or other lipid-lowering medication, all patients used calcineurin inhibitors, 88 (68%) patients used steroids, 48 (37%) patients used mycophenolate mofetil, and 27 (21%) patients used mammalian target of rapamycin receptor inhibitors.

Cardiac computed tomography

Cardiac CT was performed with a second- or third-generation dual-source CT scanner in 37 (29%) and 92 (71%) patients, respectively (Fig. 2, Table 2). The total radiation dose for the entire scan (including both coronary calcium scan and CCTA) was 2.1 (1.6–2.8) mSv when a conversion factor of 0.014 mSv/mGy/cm was used and 3.8 (2.9–5.3) mSv when a conversion factor of

0.026 mSv/mGy/cm was used. No severe allergic reactions to contrast or newly diagnosed renal failure were observed after CCTA. The coronary calcium score was calculated in all patients without prior percutaneous coronary intervention (112 of 129 (89%) patients) and showed a median calcium score of 5 (0–77) and no detectable calcium (score 0) in 51 out of 112 (40%) patients. The CCTA image quality was good or excellent in 118 (92%) patients, moderate in 9 (7%) patients, and non-diagnostic in 2 (2%) patients due to incorrect timing of contrast arrival. Patients with non-diagnostic image quality on CCTA were planned for SPECT MPI at their next outpatient clinical visit. The mean heart rate prior to the CCTA was 84 ± 15/min and 29 (22%) had a heart rate <70/min. In 82 out of 100 (82%)

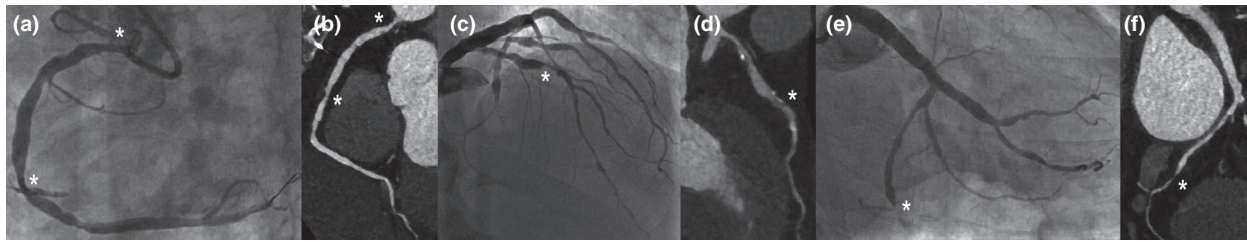


Figure 2 A case example of severe CAV in a 63-year-old man 29 years after HTx. The right coronary artery showed intermediate stenoses in the proximal and distal segments on ICA (a) and CCTA (b). The left anterior descending artery showed an intermediate stenosis in the middle segment on ICA (c) and CCTA (d). The circumflex artery showed severe stenosis in the distal segment on ICA (e) and CCTA (f). CAV: cardiac allograft vasculopathy; CCTA: coronary computed tomography angiography; HTx: heart transplantation; ICA: invasive coronary angiography.

Table 2. Cardiac CT findings.

Total number of patients, <i>n</i>	129
Scanner type	
Second-generation dual source	37 (29%)
Third-generation dual source	92 (71%)
Median radiation dose, mSv* (conversion factor 0.014 mSv/mGy/cm)	2.1 (1.6–2.8)
Median radiation dose, mSv* (conversion factor 0.026 mSv/mGy/cm)	3.8 (2.9–5.3)
Agatston calcium score	5 (0–77)
0	51 (40%)
1–100	36 (28%)
101–400	19 (15%)
>400	5 (4%)
Stent in situ	17 (13%)
Unknown	1 (1%)
Image quality of CCTA	
Excellent	66 (51%)
Good	52 (41%)
Moderate	9 (7%)
Non-diagnostic	2 (2%)
CCTA	
Normal [†]	80 (62%)
Non-obstructive	30 (23%)
Obstructive	19 (16%)
One-vessel	15 (12%)
Two-vessel	2 (2%)
Three-vessel	2 (2%)
CCTA—CAV classification [‡]	
0—none	76 (59%)
1—mild	27 (21%)
2—moderate	13 (10%)
3—severe	13 (10%)

Continuous data are presented as median with 25th–75th percentiles and categorical data as number of patients with percentages. CCTA: coronary computed tomography angiography.

*4 missing values.

[†]7 patients had a stent in situ but no other evidence of CAV on CCTA.

[‡]According to the International Society of Heart and Lung Transplantation (ISHLT) with a cutoff value of >50% for obstructive stenosis.

patients with a heart rate ≥ 70 /min, beta-blockers (5.0 mg (5.0–7.5 mg) intravenous metoprolol) were administered to reduce to heart rate from 90 ± 12 /min

to 77 ± 10 /min, which resulted in an overall mean heart rate during CCTA of 75 ± 11 /min. No severe side effects from beta-blockers including conduction

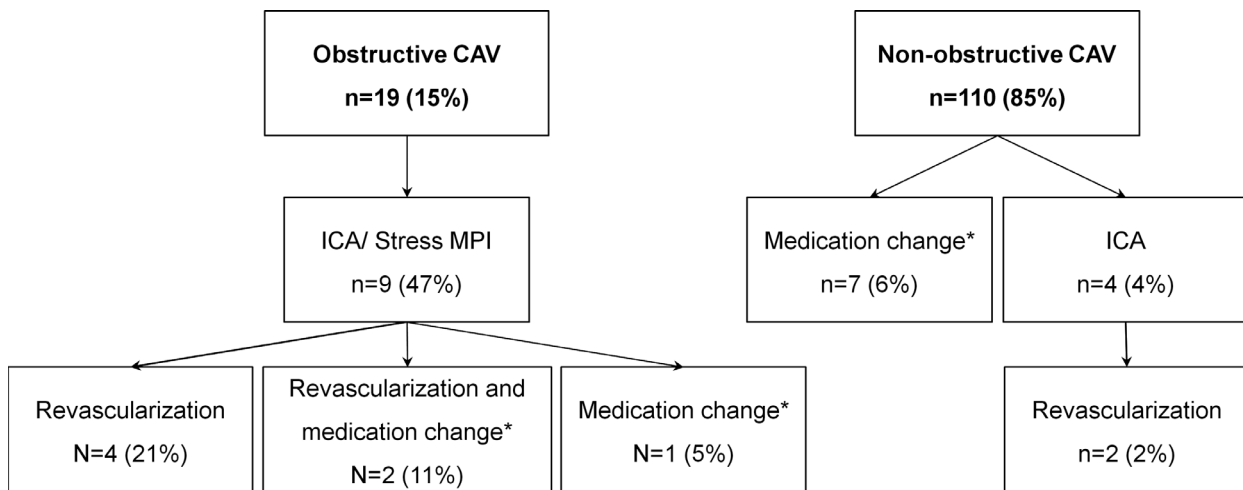


Figure 3 Medical management after 90 days of follow-up. CAV: cardiac allograft vasculopathy; CCTA: coronary computed tomography angiography; ICA: invasive coronary angiography; MPI: myocardial perfusion imaging. *Directly related to CCTA findings.

disorders or hypotension were observed. In patients that did not receive beta-blockers when indicated, this was due to logistics ($n = 14$), pacemaker-based rates ≥ 70 /min ($n = 2$), hemodialysis ($n = 1$), or patient refusal ($n = 1$).

Coronary computed tomography findings

CCTA showed obstructive coronary lesions ($\geq 50\%$ stenosis) in 19 out of 129 (15%) patients of which 15 (12%) patients had new obstructive stenosis in primary vessels ($n = 10$) or side branches ($n = 5$) and 4 (3%) patients had known obstructive CAV. Of those with known obstructive CAV, 3 patients had stenoses that were determined not to be suitable for coronary intervention (e.g., vessel diameter < 1.5 mm, total coronary occlusions) based on previous ICA and 1 patient had non-obstructive CAV on a recently performed ICA. Out of the 25 obstructive stenosis in 19 patients, 16 (64%) were non-calcified, 6 (24%) were calcified, and 3 (12%) were mixed. New incidental findings were observed in 6 (5%) patients, including lung nodules (malignant ($n = 1$) and nonmalignant ($n = 1$)), suspected atrial thrombus ($n = 2$), apical left ventricular hypertrophy ($n = 1$), and pulmonary infection ($n = 1$).

Clinical follow-up

After 90 days of follow-up, nine out of 19 (47%) patients with obstructive CAV on CCTA underwent additional tests to assess the coronary arteries including 1 SPECT MPI and 9 ICA. Eight out of 9 (89%) patients

showed obstructive CAV on ICA of whom 4 patients underwent coronary revascularization, 2 patients underwent coronary revascularization and revision in medical therapy, and in 1 patient medical therapy was revised (Fig. 3, Table S1). Changes in medication consisted of initiating and increasing statins or other lipid-lowering medication in 2 patients and changing mycophenolate mofetil to mammalian target of rapamycin receptor inhibitors in 1 patient. Ten out of 19 (53%) patients with obstructive CAV on CCTA did not undergo any additional tests as coronary stenoses were determined not to be suitable or critical enough for coronary intervention based on previous ICA or stenosis severity and location on CCTA. Four out of 110 (4%) patients with non-obstructive CAV on CCTA underwent ICA including 3 patients in which a stenosis could not be excluded and 1 patient who developed non-sustained ventricular tachycardia within 90 days after CCTA. Two out of 4 patients (50%) showed obstructive CAV on ICA and underwent coronary revascularization. Medication use was revised due to CCTA findings in 7 out of 110 (6%) patients with non-obstructive CAV on CCTA and consisted of initiating or increasing statins or other lipid-lowering medication in 6 patients and changing mycophenolate mofetil to mammalian target of rapamycin receptor inhibitors in 3 patients. Between 90-day and 1-year follow-up, 3 patients underwent ICA and none of the patients underwent additional noninvasive coronary tests. Two out 3 patients underwent ICA because of angina symptoms, one of whom had one-vessel disease and one had non-obstructive disease on their prior CCTA, and both had non-obstructive CAV

on ICA. One out of 3 patients had known severe CAV and underwent ICA and percutaneous coronary revascularization because of non-sustained ventricular tachycardia, whose prior CCTA did not show progression of known severe CAV. After 1 year, MACE was observed in 3 patients of which 1 patient undergoing percutaneous coronary revascularization suffered from no reflow after stenting resulting in a myocardial infarction type 4a and 2 patients died of non-cardiac causes.

Discussion

Main findings

In this study, we describe our clinical experience with the introduction of CCTA as first-line imaging modality for the detection of CAV. We demonstrate that (1) CCTA can be successfully implemented in the majority of HTx patients with high image quality and low radiation dose and (2) CCTA allows for clinical detection of CAV with limited need for additional invasive testing.

Feasibility of CCTA for the detection of CAV

ICA is still the golden standard for the detection of CAV, but is associated with patient discomfort, adverse events such as bleeding complications, stroke, and coronary artery dissection, and higher cost [10]. In contrast, CCTA can be performed at the outpatient clinic with an examination duration of about 30 minutes (including preparation time) and at a lower cost. CCTA has shown to detect early-stage CAV and obstructive (stenosis >50%) CAV with high negative predictive values (94% and 99%) and moderate positive predictive values (79% and 73%), confirming its value as a gatekeeper for ICA [5]. Yet, the clinical implementation of CCTA as a first-line image modality for the detection of CAV has been hampered due to lower image quality and higher radiation dose in patients with elevated heart rates [3]. Recent studies have shown that contemporary CT technology reaches good diagnostic image quality in HTx patients at reasonable radiation exposure [6,7,11,12]. In the present study with a large real-world HTx population with relatively high heart rates, similar results were observed. Additionally, beta-blockers are typically used prior CCTA to reduce the heart rate and optimize the image quality [9]. However, previous studies have made limited use of beta-blockers in HTx patients prior CCTA, because there is no consensus on the effect and safety of beta-blockers in

denervated hearts [11,13,14]. In this study, most patients received intravenous beta-blockers after consultation with the transplant cardiologist, which safely reduced the heart rate by 15%, suggesting the potential clinical value of beta-blockers in HTx patients prior CCTA. Alternatively, ivabradine has also shown to safely and effectively lower heart rates in HTx patients in sinus rhythm [11,14].

Applicability of CCTA for the detection of CAV

CCTA was successfully implemented in three-quarters of the HTx patients scheduled for noninvasive imaging for the detection of CAV. Renal impairment was the most frequent reason why patients could not undergo CCTA, followed by known iodine contrast allergy (i.e., mild to anaphylaxis) and logistical reasons. This addresses important considerations for the clinical implementation of CCTA as a first-line imaging modality for the detection of CAV. Firstly, patients with severe renal impairment have a much higher risk for iodine contrast-induced acute kidney injury, which makes the use of iodine contrast unfavorable in these patients [15]. Therefore, CCTA should be avoided in patients, especially since ICA requires at least similar amounts of iodine contrast medium. Secondly, CT scanners with high temporal resolutions are preferred to deliver high image quality and low radiation dose in HTx patients, because the majority of these patients have resting heart rates >70/min. Overall, CCTA is an attractive alternative to ICA in most HTx patients with more ease for the patients and logistics.

Future perspectives

Although ICA is advised for routine surveillance of CAV, we believe that CCTA can be used as a gatekeeper for ICA, which can have additional clinical implications. Firstly, medication including statins, mycophenolate mofetil, and mammalian target of rapamycin receptor inhibitors has shown favorable clinical outcomes but has also associated significant side effect [16,17]. The timing of initiation of this kind of medication is therefore crucial to optimize clinical impact and outcome in each specific patient. CCTA allows quantitative coronary wall analysis with good agreement with intravascular ultrasound and has shown to be feasible to assess the progression of early-stage CAV [5,11,12]. Moreover, Rohnean et al. investigated the prognostic value of CCTA in HTx patients and showed that patients without CAV on CCTA were free from cardiovascular events

after 5-year follow-up [18]. Therefore, early detection of CAV by CCTA could be valuable to tailor preventive and immunosuppressive therapy. Secondly, new incidental findings were found in 5% of the patients, which may also benefit the prognosis of other transplant-related diseases (e.g., malignancies). Finally, coronary calcium scoring is widely used as a cardiovascular risk modifier in asymptomatic non-transplanted patients and has been shown to correlate well with the severity of CAV on ICA [19]. However, the clinical value of coronary calcium scoring in HTx patients has yet to be determined.

Limitations of CCTA for the detection of CAV

CCTA has a high sensitivity but a lower specificity [5]. This is the reason that some cases in this study with known or potential severe CAV were not converted to CCTA. Additionally, CCTA lacks the ability to evaluate microvascular CAV, which has been shown to precede epicardial CAV and independently predicts long-term survival [20]. Furthermore, CCTA does not allow a functional assessment of CAV, making it difficult to determine whether a stenosis affects myocardial perfusion. Alternatively, MPI allows for a functional assessment of epicardial and microvascular disease without the need for iodized contrast medium. Therefore, MPI could be valuable in selected cases. Moreover, emerging CT technologies including CT-derived fractional flow reserve and CT MPI offer the potential to functionally assess the coronary arteries without using additional modalities [21,22]. Further investigations of these methods are needed to confirm this in HTx patients.

Conclusions

CCTA can be safely and successfully implemented as a noninvasive alternative for routine detection of CAV in HTx patients with good image quality and low radiation dose. CCTA allows CAV evaluation with limited need for additional invasive testing.

Author contribution

F.M.A. Nous involved in investigation, formal analysis, writing original draft preparation, final approval of the manuscript, and agreed to be accountable for all aspects of the work. S. Roest involved in investigation, writing—reviewing and editing, final approval of the manuscript, and agreed to be accountable for all aspects of the work. E.D. van Dijkman involved in investigation, writing—reviewing and editing, final approval of the manuscript, and agreed to be accountable for all aspects of the work. J.J. Brugts, M. Attrach, A. Hirsch, A.A. Constaninescu, K. Nieman, and K. Caliskan involved in resources, writing—reviewing and editing, final approval of the manuscript, and agreed to be accountable for all aspects of the work. O.C. Manintveld and R.P.J. Budde involved in investigation, conceptualization, methodology, supervision, writing—reviewing and editing, final approval of the manuscript, and agreed to be accountable for all aspects of the work.

Funding

This research did not receive any specific grant from funding agencies in the public, commercial, or not-for-profit sectors.

Conflict of interest

Dr. Budde reports institutional research support to the Erasmus MC from Siemens Healthineers outside he submitted work. Dr. Nieman reports unrestricted institutional grants from Siemens Healthineers, Bayer, and HeartFlow Inc., outside the submitted work. All other authors have not to disclose.

SUPPORTING INFORMATION

Additional supporting information may be found online in the Supporting Information section at the end of the article.

Table S1. Findings of CCTA and additional tests per patient.

REFERENCES

1. Lund LH, Edwards LB, Kucheryavaya AY, *et al.* The registry of the international society for heart and lung transplantation: Thirty-second official adult heart transplantation report—2015; focus theme: early graft failure. *J Heart Lung Transplant* 2015; **34**: 1244.
2. Mehra MR, Crespo-Leiro MG, Dipchand A, *et al.* International Society for Heart and Lung Transplantation working formulation of a standardized nomenclature for cardiac allograft vasculopathy-2010. *J Heart Lung Transplant* 2010; **29**: 717.

3. Costanzo MR, Dipchand A, Starling R, et al. The international society of heart and lung transplantation guidelines for the care of heart transplant recipients. *J Heart Lung Transplant* 2010; **29**: 914.
4. Tavakol M, Ashraf S, Brener SJ. Risks and complications of coronary angiography: a comprehensive review. *Glob J Health Sci* 2012; **4**: 65.
5. Wever-Pinzon O, Romero J, Kelesidis I, et al. Coronary computed tomography angiography for the detection of cardiac allograft vasculopathy: a meta-analysis of prospective trials. *J Am Coll Cardiol* 2014; **63**: 1992.
6. Beitzke D, Berger-Kulemann V, Schopf V, et al. Dual-source cardiac computed tomography angiography (CCTA) in the follow-up of cardiac transplant: comparison of image quality and radiation dose using three different imaging protocols. *Eur Radiol* 2015; **25**: 2310.
7. Bartykowszki A, Kolossváry M, Jermendy ÁL, et al. Image quality of prospectively ECG-triggered coronary CT angiography in heart transplant recipients. *AJR Am J Roentgenol* 2018; **210**: 314.
8. Agatston AS, Janowitz WR, Hildner FJ, Zusmer NR, Viamonte M Jr, Detrano R. Quantification of coronary artery calcium using ultrafast computed tomography. *J Am Coll Cardiol* 1990; **15**: 827.
9. Leipsic J, Abbara S, Achenbach S, et al. SCCT guidelines for the interpretation and reporting of coronary CT angiography: a report of the Society of Cardiovascular Computed Tomography Guidelines Committee. *J Cardiovasc Comput Tomogr* 2014; **8**: 342.
10. Genders TS, Petersen SE, Pugliese F, et al. The optimal imaging strategy for patients with stable chest pain: a cost-effectiveness analysis. *Ann Intern Med* 2015; **162**: 474.
11. Karolyi M, Kolossvary M, Bartykowszki A, et al. Quantitative CT assessment identifies more heart transplanted patients with progressive coronary wall thickening than standard clinical read. *J Cardiovasc Comput Tomogr* 2019; **13**: 128.
12. Foldyna B, Sandri M, Luecke C, et al. Quantitative coronary computed tomography angiography for the detection of cardiac allograft vasculopathy. *Eur Radiol* 2020; **30**: 4317.
13. Ciarka A, Lund LH, Van Cleemput J, Voros G, Droogne W, Vanhaecke J. Effect of heart rate and use of beta blockers on mortality after heart transplantation. *Am J Cardiol* 2016; **118**: 1916.
14. Doesch AO, Celik S, Ehlermann P, et al. Heart rate reduction after heart transplantation with beta-blocker versus the selective If channel antagonist ivabradine. *Transplantation* 2007; **84**: 988.
15. Morcos R, Kucharik M, Bansal P, et al. Contrast-induced acute kidney injury: review and practical update. *Clin Med Insights Cardiol* 2019; **13**: 1179546819878680.
16. Asleh R, Briasoulis A, Kremers WK, et al. Long-term sirolimus for primary immunosuppression in heart transplant recipients. *J Am Coll Cardiol* 2018; **71**: 636.
17. Tremblay-Gravel M, Racine N, de Denus S, et al. Changes in outcomes of cardiac allograft vasculopathy over 30 years following heart transplantation. *JACC Heart Fail* 2017; **5**: 891.
18. Rohnean A, Houyel L, Sigal-Cinqualbre A, To NT, Elfassy E, Paul JF. Heart transplant patient outcomes: 5-year mean follow-up by coronary computed tomography angiography. *Transplantation* 2011; **91**: 583.
19. Gunther A, Andersen R, Gude E, et al. The predictive value of coronary artery calcium detected by computed tomography in a prospective study on cardiac allograft vasculopathy in heart transplant patients. *Transpl Int* 2018; **31**: 82.
20. Hiemann NE, Wellnhofer E, Knosalla C, et al. Prognostic impact of microvasculopathy on survival after heart transplantation: evidence from 9713 endomyocardial biopsies. *Circulation* 2007; **116**: 1274.
21. Oebel S, Hamada S, Higashigaito K, et al. Comprehensive morphologic and functional imaging of heart transplant patients: first experience with dynamic perfusion CT. *Eur Radiol* 2018; **28**: 4111.
22. Douglas PS, Pontone G, Hlatky MA, et al. Clinical outcomes of fractional flow reserve by computed tomographic angiography-guided diagnostic strategies vs. usual care in patients with suspected coronary artery disease: the prospective longitudinal trial of FFR(CT): outcome and resource impacts study. *Eur Heart J* 2015; **36**: 3359.